



UNIUNEA EUROPEANĂ



GUVERNUL ROMÂNIEI



Fondul Social European
POSDRU 2007-2013



Instrumente Structurale
2007-2013



GUVERNUL ROMÂNIEI
MINISTERUL MUNCII, FAMILIEI,
PROTECȚIEI SOCIALE
ȘI PERSOANELOR VÂRSTNICE
OIRPOSDRU REGIUNEA CENTRU



UNIVERSITATEA DE MEDICINĂ ȘI
FARMACIE "CAROL DAVILA"
BUCUREȘTI

AD-COR Program inovativ de formare in domeniul cardiologiei pediatrice POSDRU/179/3.2/S/152012

Septembrie 2015

MODUL TEORETIC PATOLOGIA VALVULARA

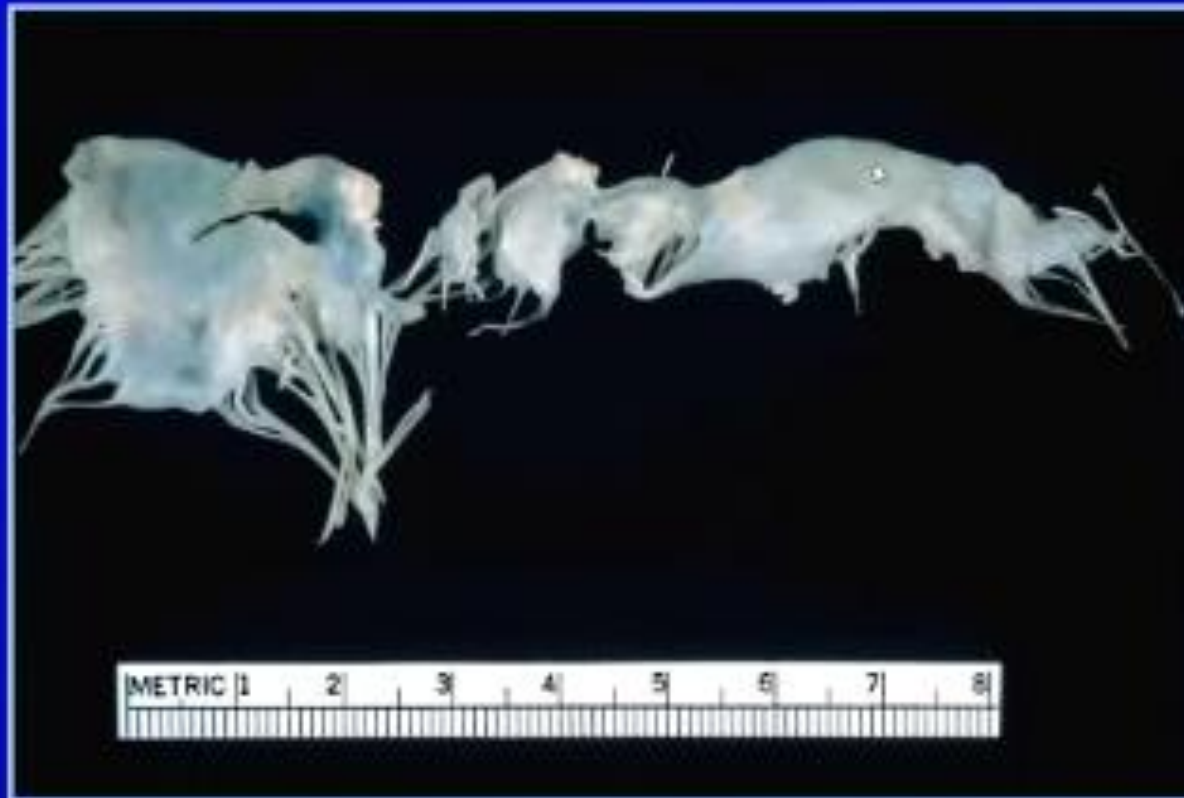Continut documentat/ validat/ prezentat de:

- ⇒ Expert formare medici: NICOLESCU Alin
- ⇒ Expert formare medici: VEDUTA Alina

A4 – Planificarea, organizarea si desfasurarea activitatilor de formare a medicilor in domeniul cardiologiei pediatrice

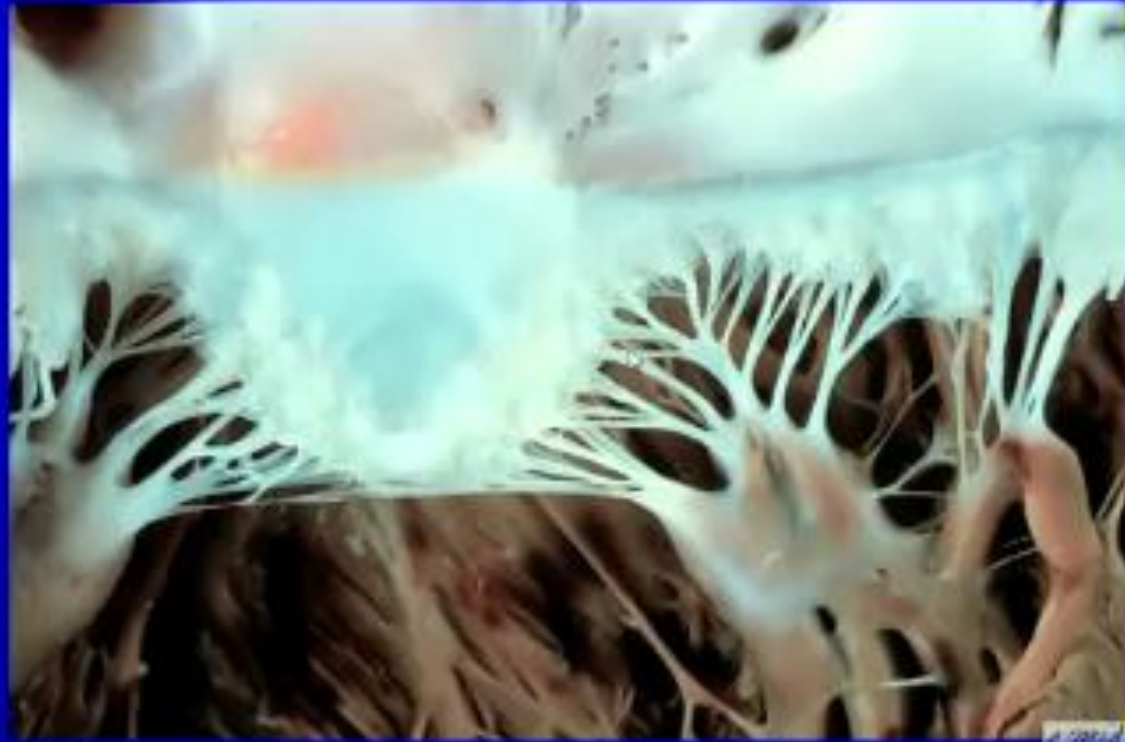
Valva mitrala (VM)

- * Cunoasterea precisa a anatomiei valvei mitrale si interpretarea corecta a studiilor ecocardiografice sunt esentiale in intelegerea mecanismelor de regurgitare si stenoza, stabilirea localizarii disfunctiei cuspelor (analiza valvulara segmentala) si stabilirea planului de corectie chirurgicala.

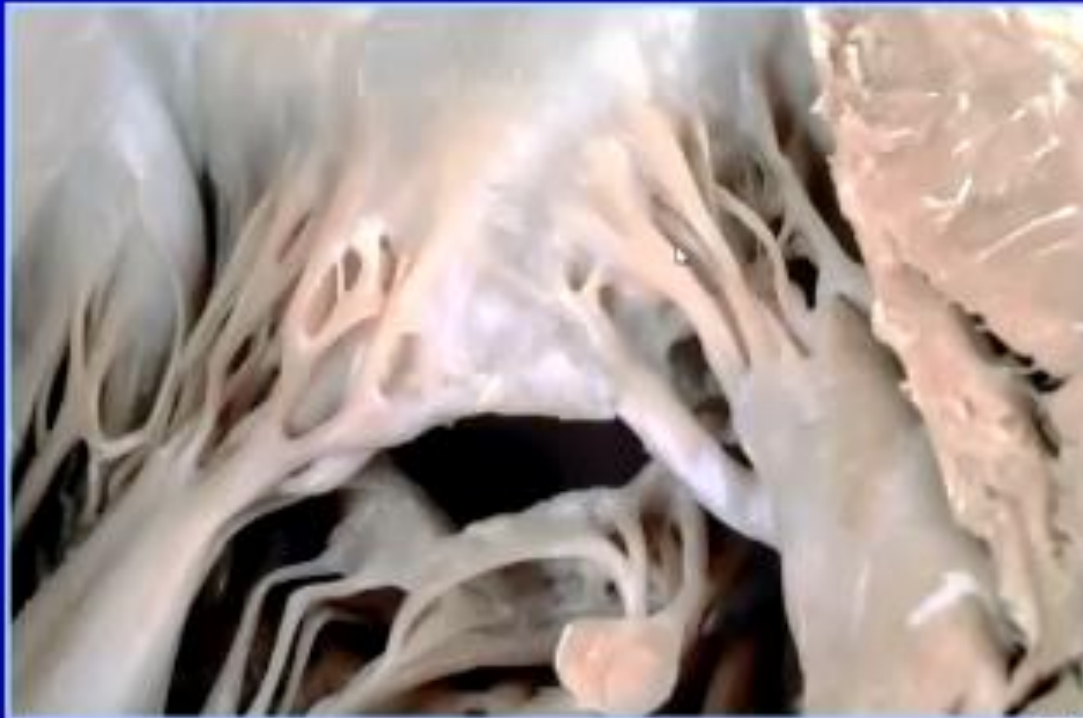

Photo

Mitral Valve: Atrial View



Mitral Valve: Ventricular View



© 2004

MAYO CLINIC 3DG

07 Apr 08

BP: 100/60mmHg

7:51:41 am

4V1c-S 42Hz

14.25MHz 120mm

MAYO PEDS

General /V

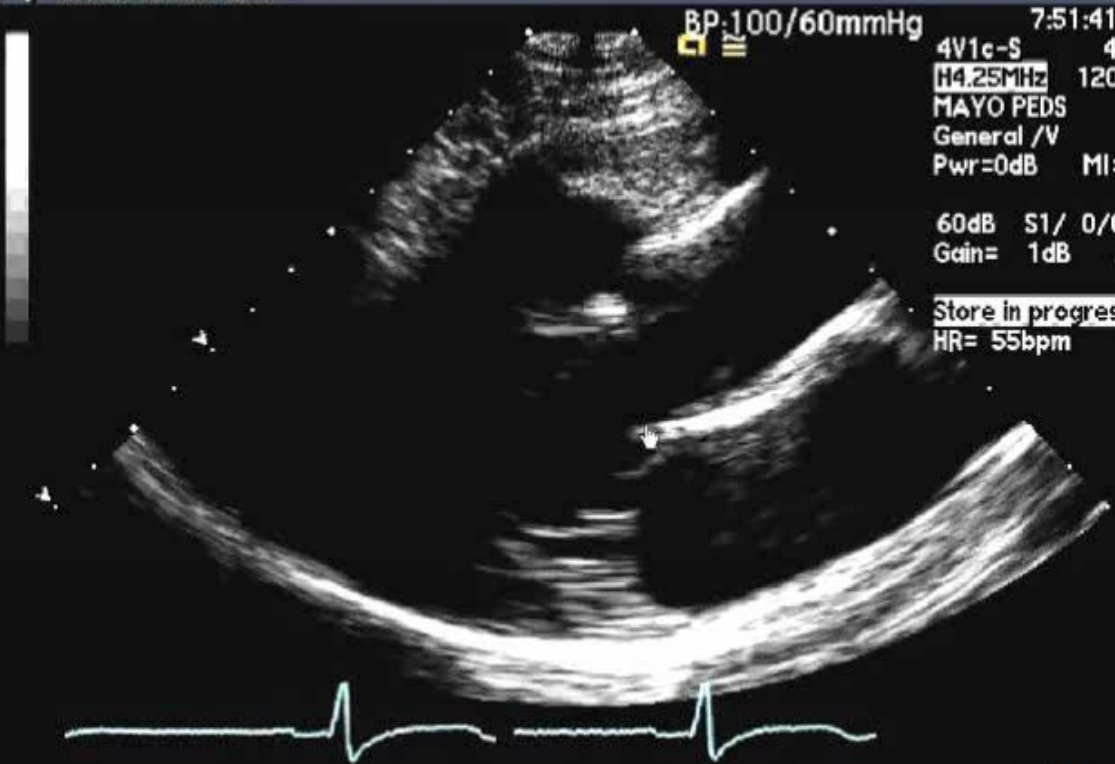
Pwr=0dB MI=1.9

60dB S1/ 0/0/ 6

Gain= 1dB Δ=1

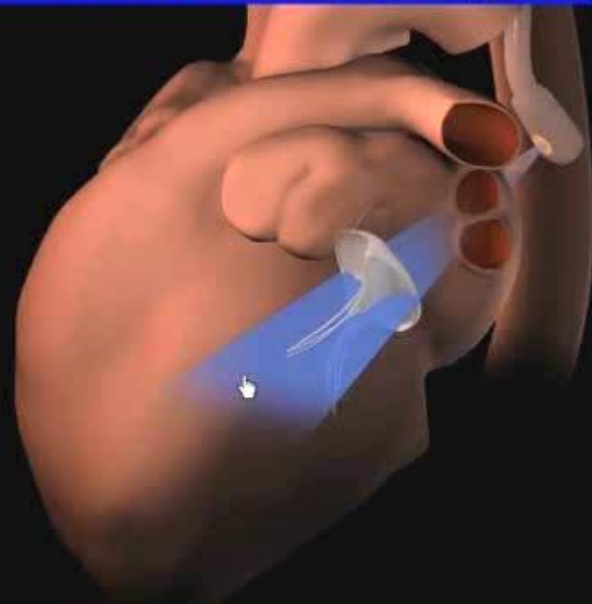Store in progress

HR= 55bpm



eMed

3D Echocardiography



MAIO CLINIC

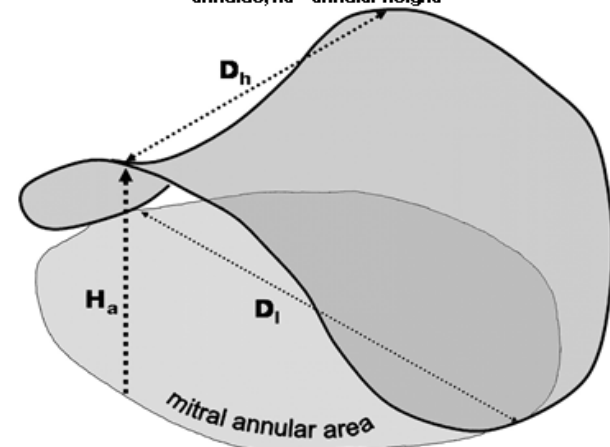
eMed



Anatomia Valvei mitrale (2)

- * Non-planearitatea inelului si cuspelor este rationala:
 - baza ventriculului stang scade în circumferință timpul sistolei dar valvulele nu se contracta, zona circulară mitrală se poate reduce într-un fel de pliere care se realizează prin scaderea distanței dintre punctele înalte și joase ale inelului.
 - forma de sa oferă o configurație capabila să reziste solicitărilor de presiune impuse de ventriculului stâng în timpul sistolei.

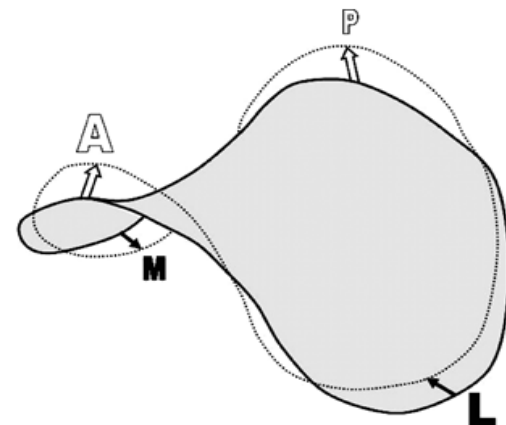
Schematic presentation of the nonplanar, saddle-shaped mitral valve and its characteristic parameters: D_h – distance between high points; D_l – distance between low points of the annulus; H_a – annular height.



Valoic Gabriel et al. Eur J Echocardiogr 2005;6:443-454

cop:

Schematic presentation of the dynamics of the mitral annulus.



Valoic Gabriel et al. Eur J Echocardiogr 2005;6:443-454



Causes and Anatomy

Rheumatic MS

Commissural fusion

Degenerative MS

Annular calcification

Associated with elderly, hypertension, atherosclerosis and aortic stenosis

Congenital MS

Abnormalities of subvalvular apparatus

Other: Systemic lupus, infiltrative disease, carcinoid heart disease, drug-induced valve disease

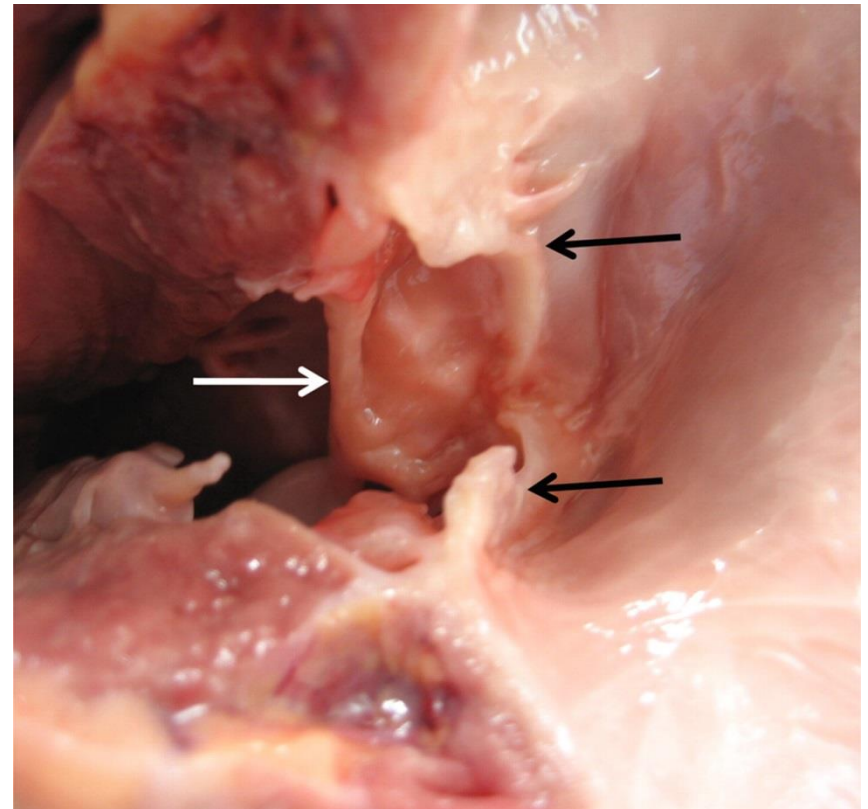
Stenoza mitrala congenitala

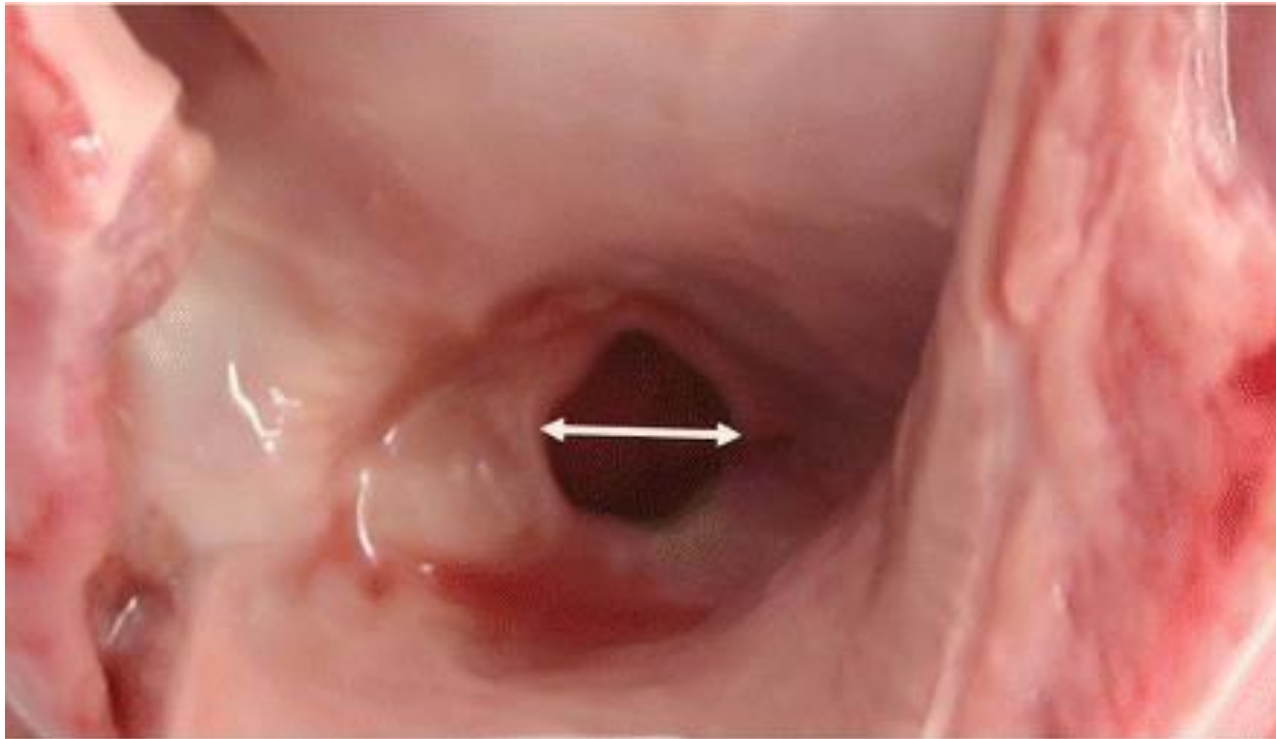
- * 1. Inel supravavular mitral
- * 2. Valva mitrala in parasuta
- * 3. Fuziune mm papilari –comisuri

Leziuni stenotice

1. Inel supravavular mitral(1)

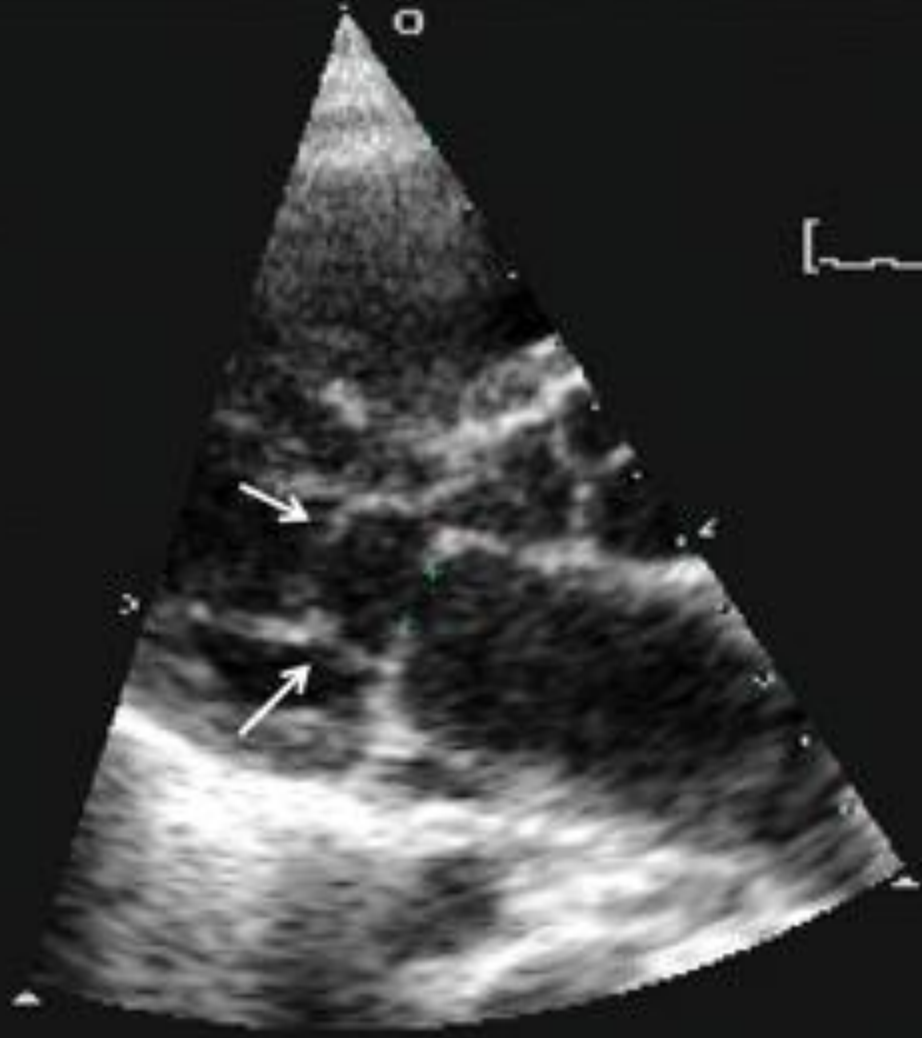
- * Cauza comuna de stenoza mitrala supravavulara
- * Este o structura fibroasa atasata inelului valvular
- * Poate fi legat de prezenta unui sinus coronar dilatat ca in persistenta de VCS stg.





MI: 1.6
54 1.8/3.6
04 FEB 04
A-DIST: 128 cm
2/0/C/H1
INST. BOLI CARDIO
VASC. CC ILIESCU
Adult

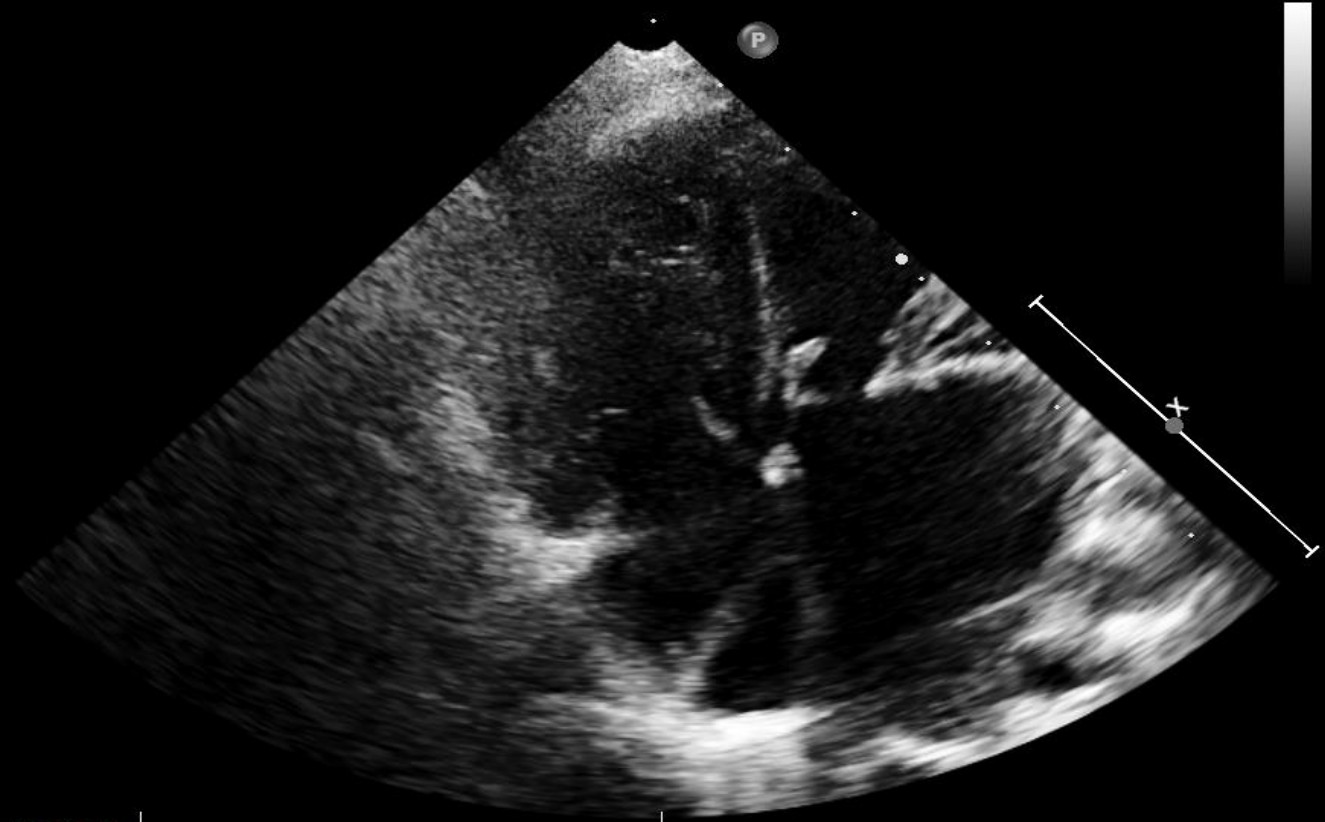
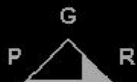BP
GAIN 56
COMP 70
1268PM
13CM
25HZ



T
R
1.6 3.6
0.44
SEC

FR 61Hz
9.0cm

2D
66%
C 50
P Off
Res



WL: 127 WW: 254 [D]

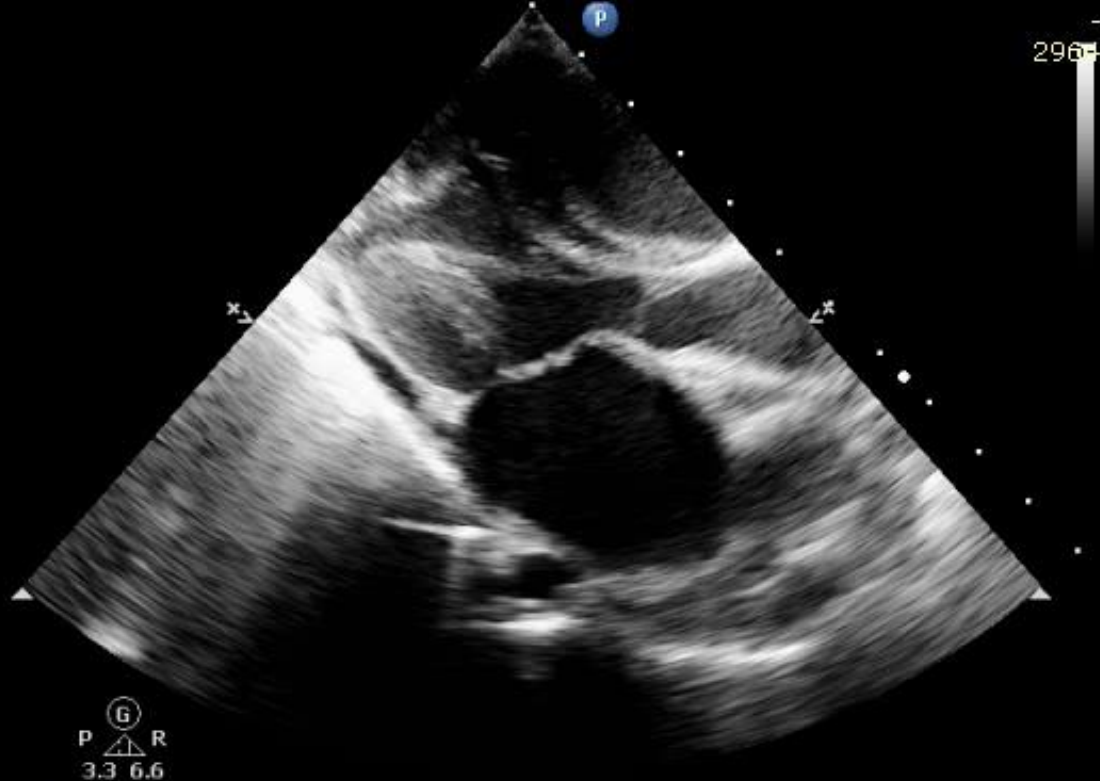
12/4/2014 12:18:47 PM

PHILIPS MUSTAFA SINEM
Se: 1 15-03-17-174446

MI 1.2 MUSTAFA SINEM
TIS 0.9 15-03-17-174446
5:48:37 PM

CORD 10-14
S8-3
92 Hz
11.0cm

2D
HGen
Gn 37
C 46
2/2/0
75 mm/s



WL: 128 WW: 256 [D]

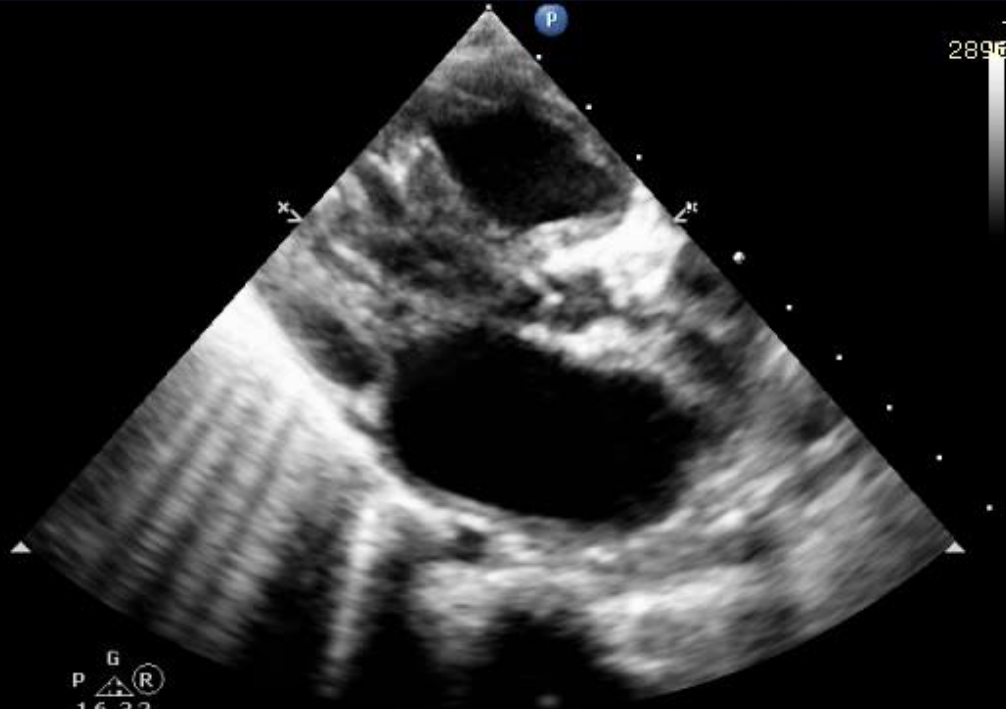
3/17/2015 5:48:40 PM

Im: 11/91 MUSTAFA, SINEM
Se: 1 15-03-12-162439

MI 1.1 MUSTAFA2 SINEM
TIS 0.4 15-03-12-162439
4:26:20 PM

CORD1
S5-1
40 Hz
10.0cm

2D
HRes
Gn 16
C 50
3/3/4
75 mm/s



WL: 128 WW: 256 [D]

3/12/2015 4:26:23 PM

Leziuni stenotice

2.Valva mitrala in parasuta (1)

- * Poate fi descoperita ca leziune izolata sau in cadrul Sdr. Shone
 - * Cel mai frecvent se asociaza cu muschi papilar unic dar poate exista un spectru larg de anomalii ale aparatului suspensor de la fuziunea completa a muschilor papilari pana la aspect relativ normal al cordajelor cu mobilitate buna a cuspelor.

Similarity of a Parachute to the Mitral Valve

MYHEART.NET



Valve leaflet

Valve Chords

Papillary muscle

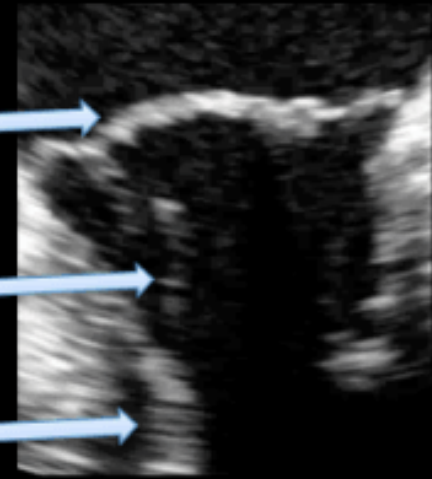
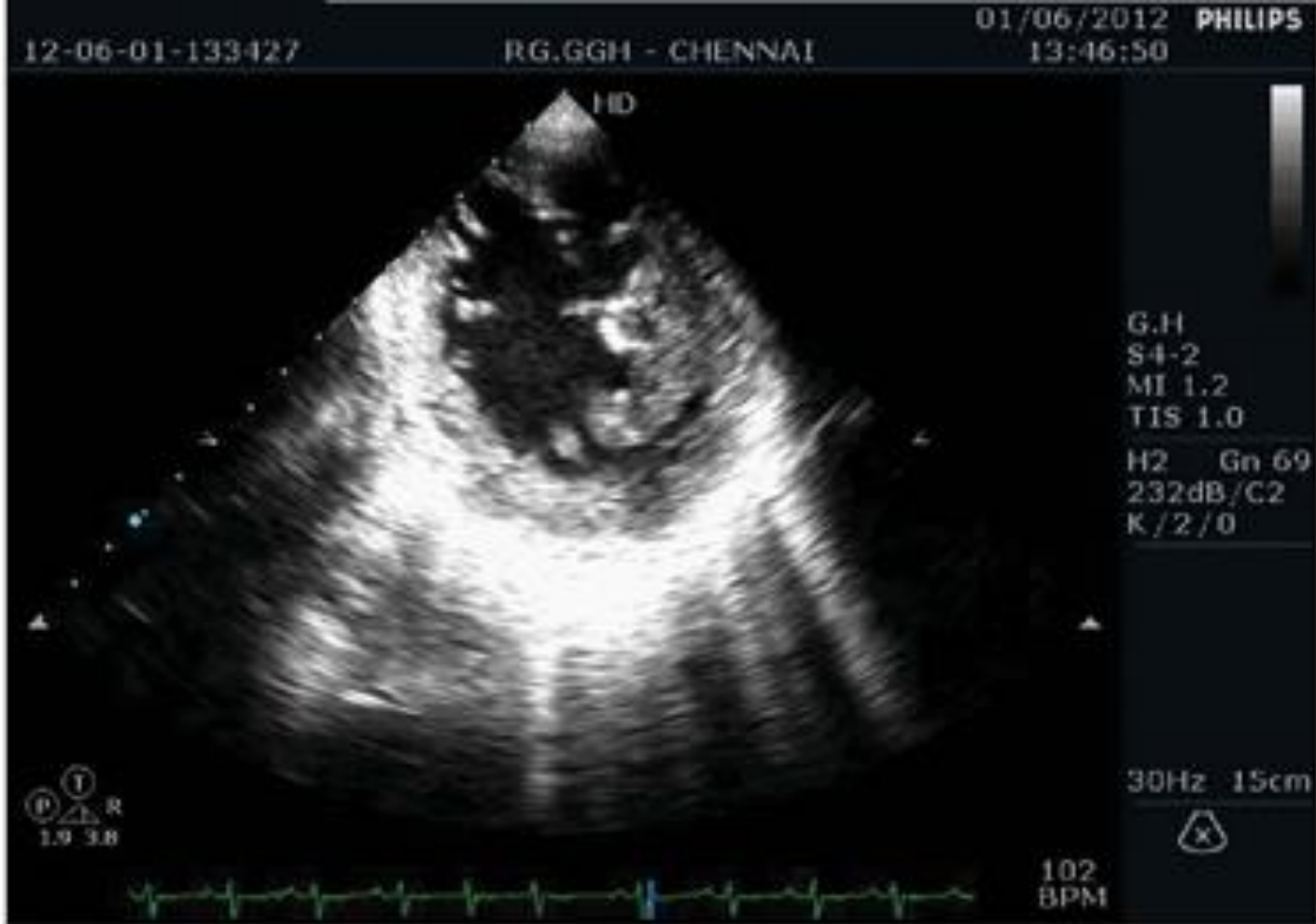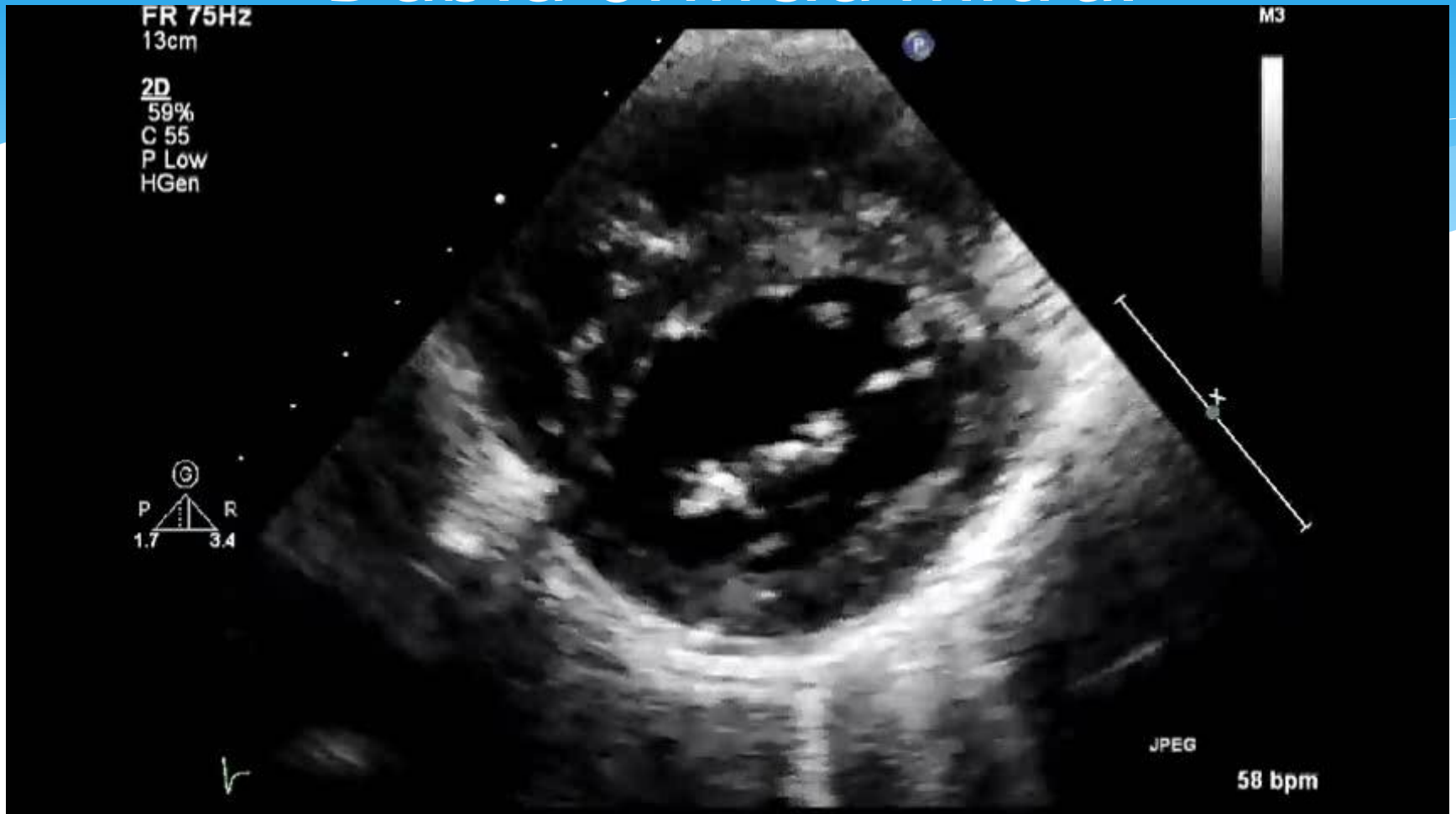


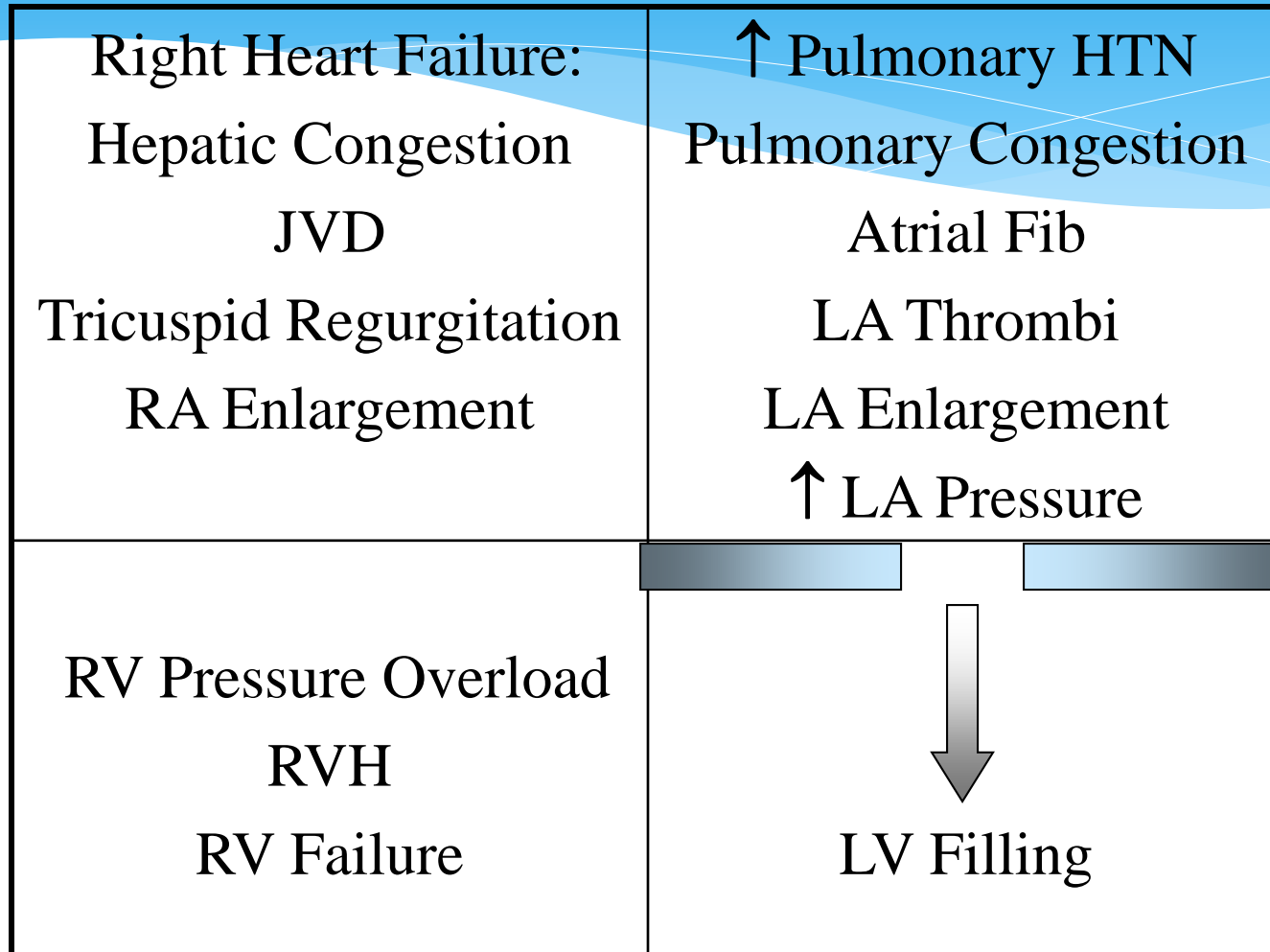


Fig. 2 : Parasternal short axis view showing single papillary muscle

Dublu orificiu mitral



Mitral Stenosis: Pathophysiology

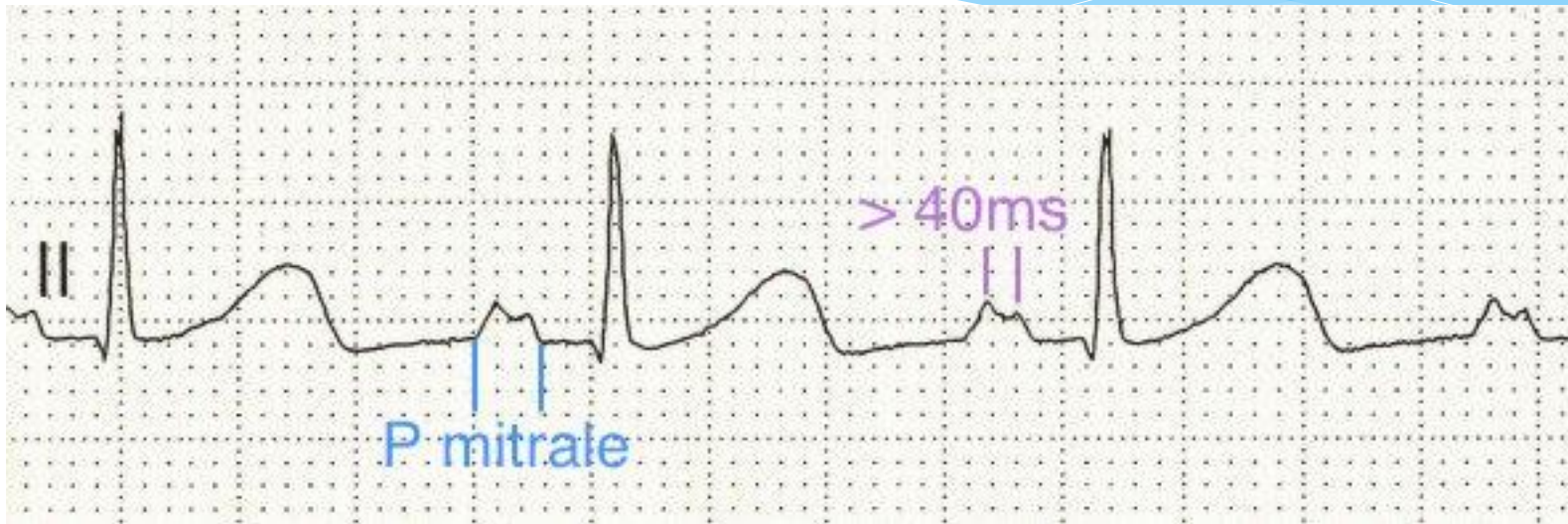


Stenoza mitrala

simptomatologie si examen clinic

- * Dispnee de efort, tahipnee
- * Falimentul cresterii
- * Infectii respiratorii recurente
- * Examen clinic: suflu diastolic apical (“uruitura diastolica”), Z1 intarit, clacment de deschidere al mitralei

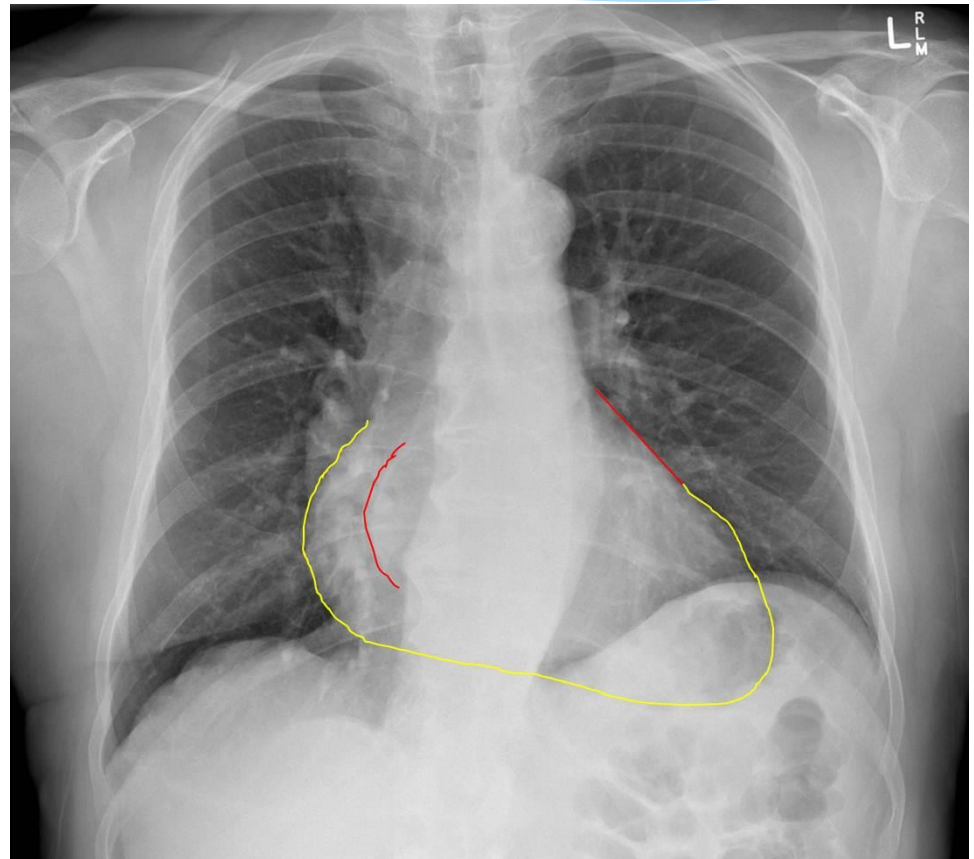
Electrocardiografie



- * Unda P cu aspect “mitral” (bifida)
- * Semne de suprasolicitare VD in cazul aparitiei HTP

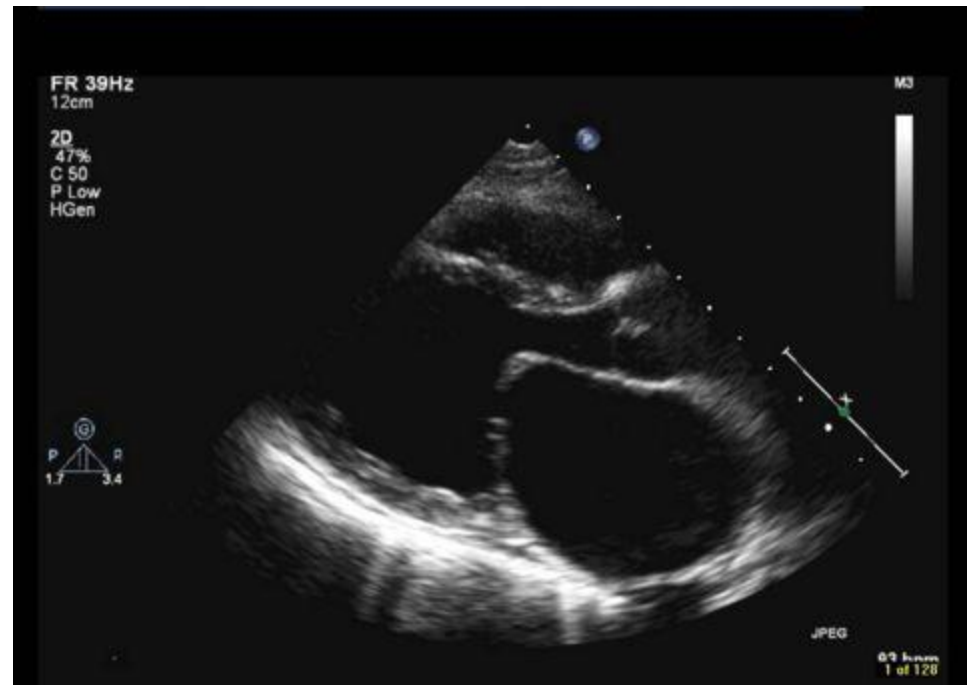
Radiografie cardio-pulmonara

- * Bombarea arcului inferior drept prin dilatarea AS
- * Bombarea arcului mijlociu stang in cazul aparitiei dilatarii AP



Stenoza mitrala evaluare ecocardiografica

- * In majoritatea cazurilor ecocardiografia ofera elemente care sugereaza etiologia dar informatiile trebuie integrate in context clinic
- * Sectiuni recomandate:
 - * Parasternal ax lung
 - * Parasternal ax scurt la nivelul VM
 - * Apical 4C si 2C



Assessment of severity of Mitral Stenosis

Severity is quantified by

- **Doppler transmitral pressure gradient**
- **Pulmonary hypertension**
- **Mitral valve area (MVA)**

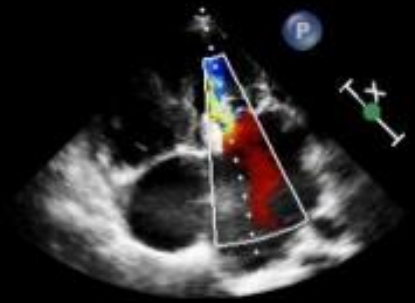	Mild	Moderate	Severe
Specific findings			
Valve area (cm ²)	>1.5	1.0-1.5	<1.0
Supportive findings			
Mean gradient (mmHg) ^a	<5	5-10	>10
Pulmonary artery pressure (mmHg)	<30	30-50	>50



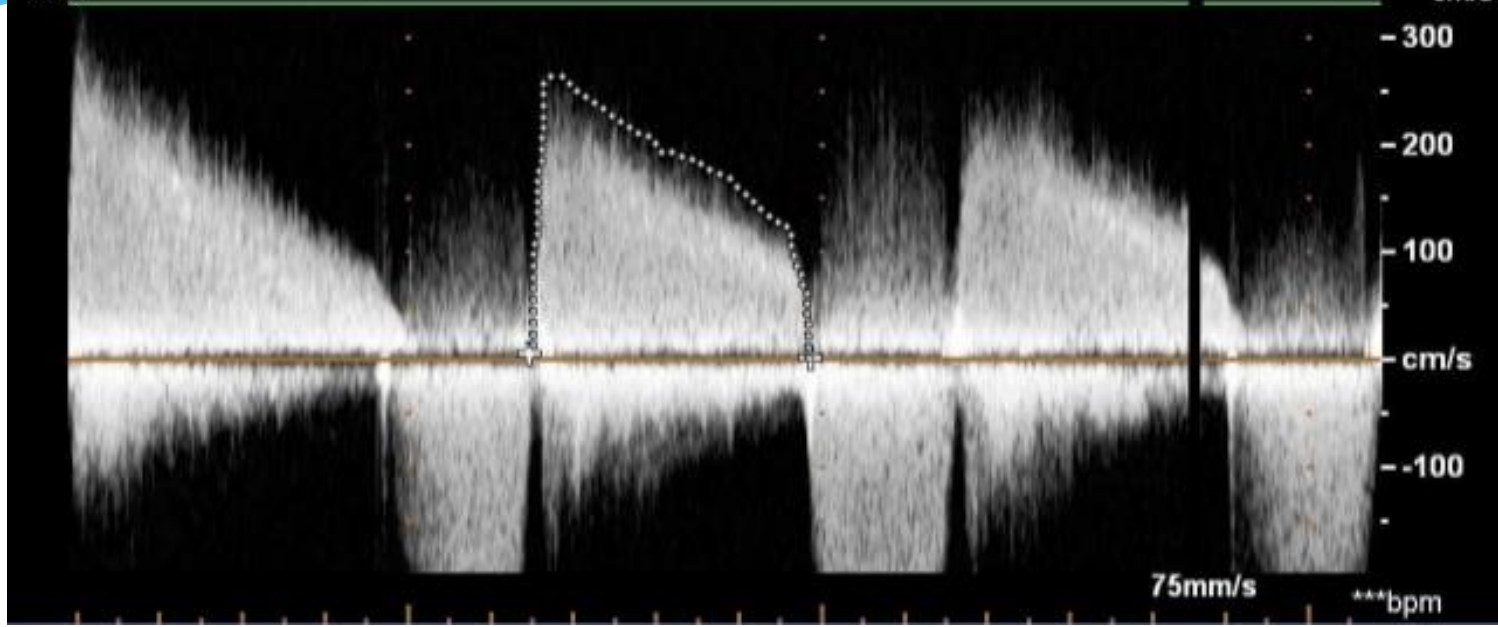
*Gradient transmitral mediu

PR 22Hz
15cm

2D
68%
C 50
P Low
HGen
CF
66%
2.5MHz
WF High
Med



Vmax 262 cm/s
Vmean 183 cm/s
Max PG 27 mmHg
Mean PG 15 mmHg
VTI 125 cm



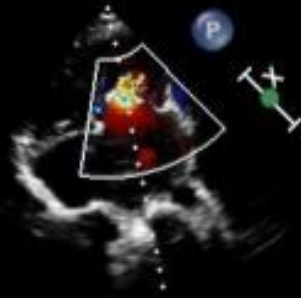PR 11Hz
17cm

2D

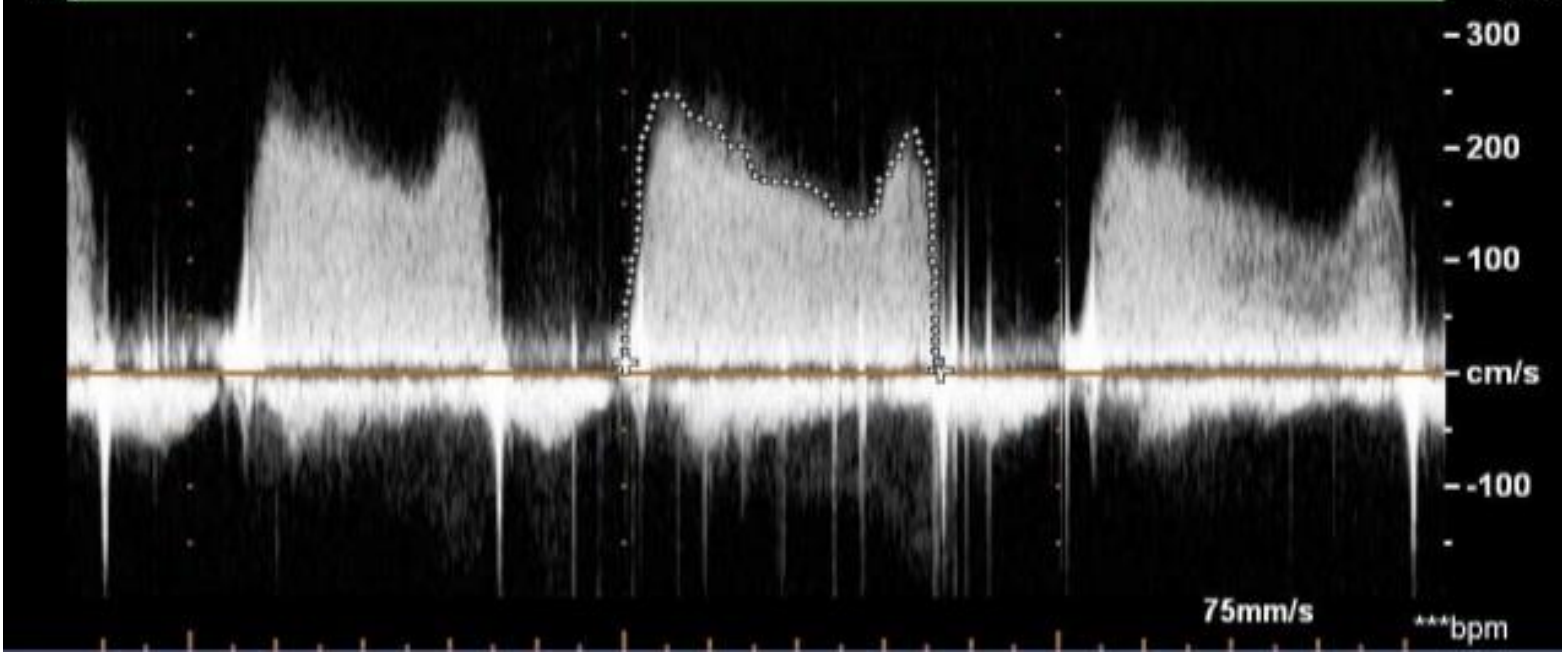
58%
C 50
P Low
HGen

CF

66%
2.5MHz
WF High
Med



❖ Vmax 247 cm/s
Vmean 181 cm/s,
Max PG 24 mmHg
Mean PG 14 mmHg
VTI 132 cm



Estimation of Pulmonary Artery Pressure

- The obstruction of flow at the mitral orifice results in pulmonary hypertension and increased pulmonary vascular resistance.
- *The degree of pulmonary hypertension is a measure of the hemodynamic burden.*
- Pulmonary artery systolic pressure (PAP) is incorporated in grading the severity of MS

<30 mm Hg – mild

30-50 mmHg – moderate

>50 mm Hg - severe

- Echocardiographically estimated RVSP is used as a surrogate for PAP, *in absence of PS.*
- RAP is estimated from size of IVC and respiratory collapsibility.

Bonow RO et al 2008 ACC/AHA guidelines

Mitral Valve Area (MVA)

- The most reliable way to determine the severity of mitral stenosis is to calculate the area of the mitral valve

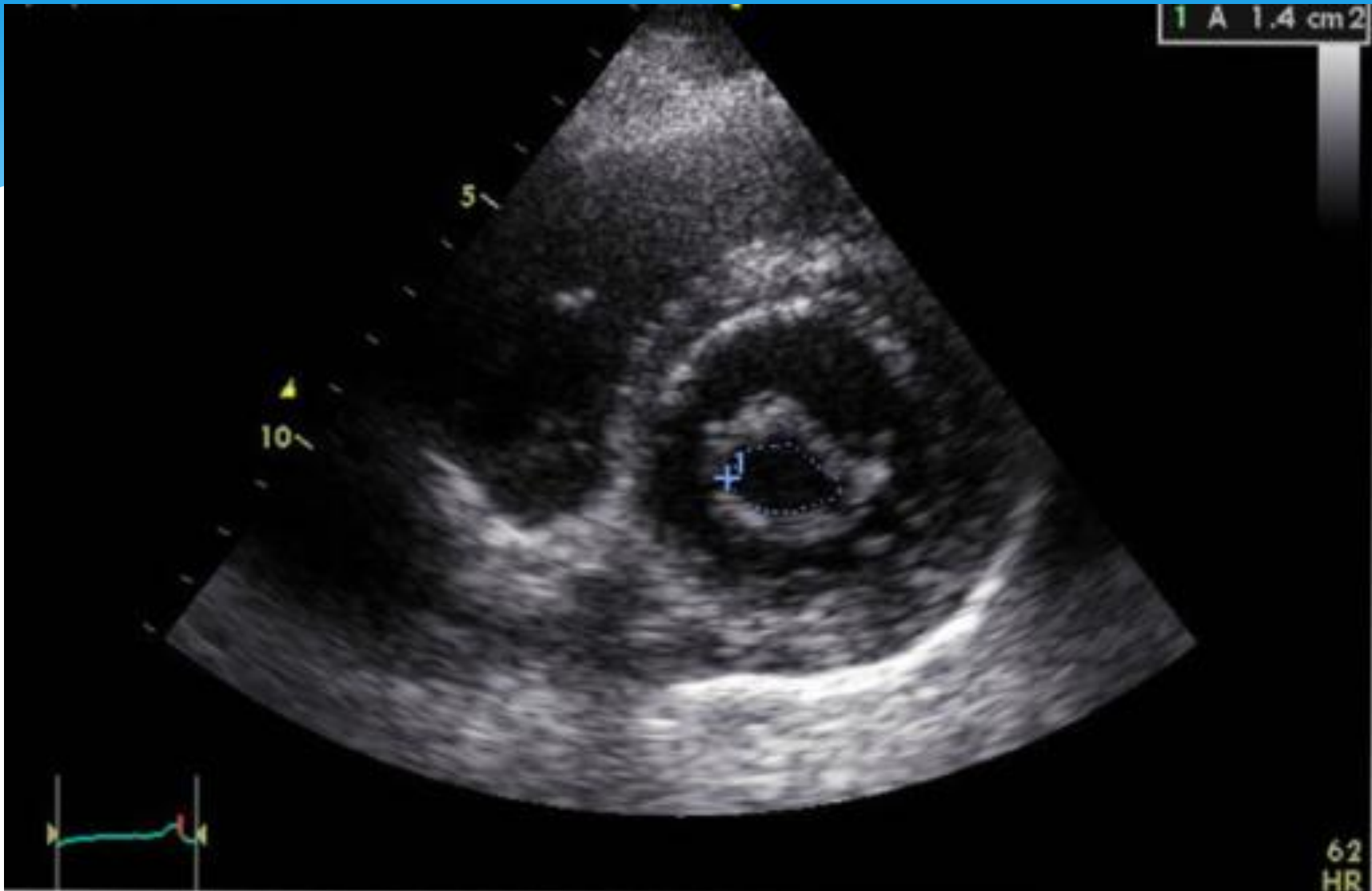
Normal - 4 to 6 cm²

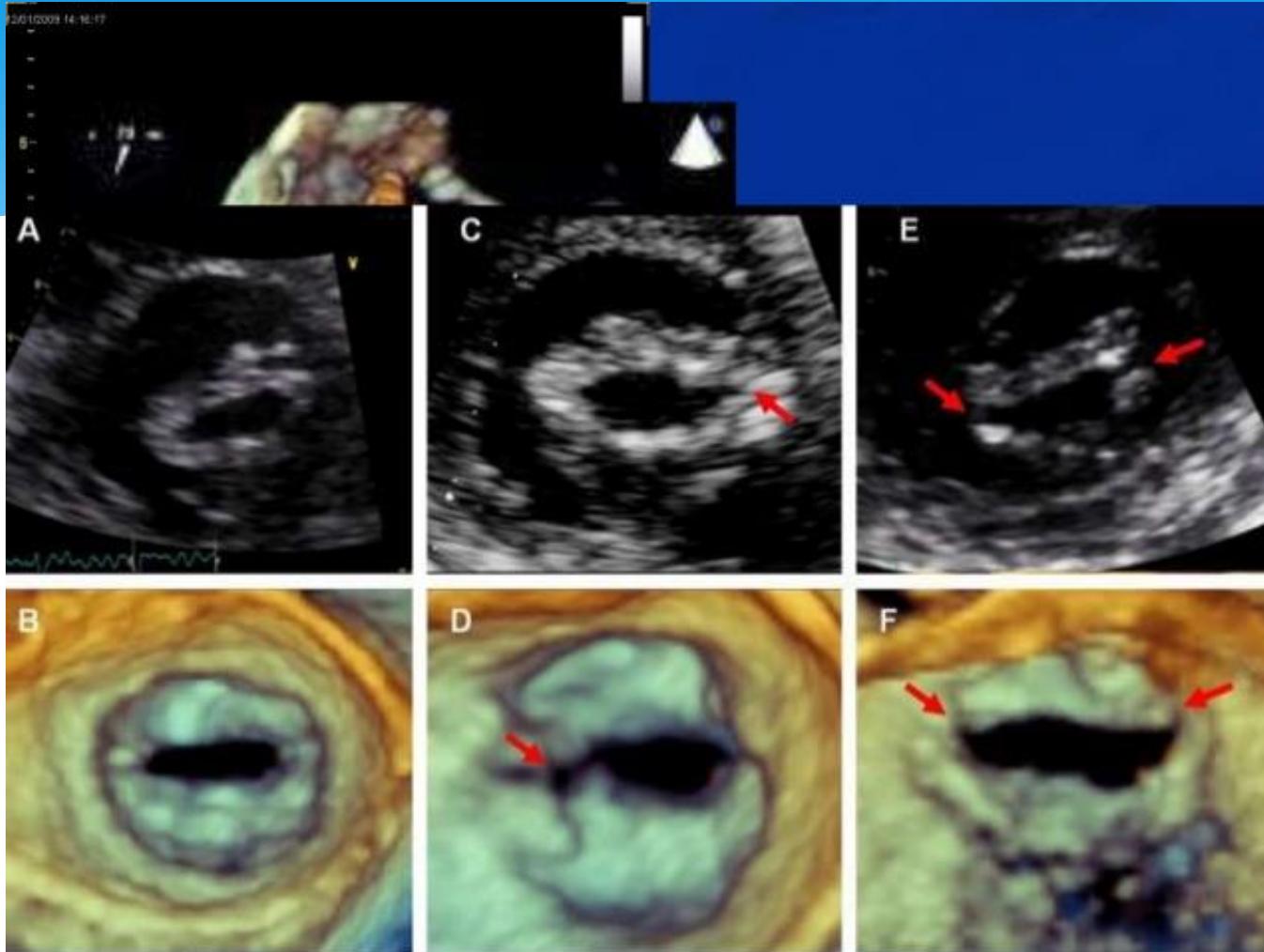
Mild - 1.6 to 2.0 cm²

Moderate - 1.1 to 1.5 cm²

Severe - 1.0 cm² or smaller

- Mitral valve area can be calculated by:
 - Pressure half-time (PHT)
 - Continuity equation
 - Proximal Isovelocity Surface Area (PISA) method
 - Planimetry





PRESSURE HALF METHOD HATLE'S FORMULA



Hatle and colleagues

- Concept of PHT as a *relatively flow independent* assessment of MS severity.
- PHT – the time taken for the transmitral pressure gradient to decay to half the value at the onset of diastole.
- Time required for the *peak velocity to decrease to $V/\sqrt{2}$ or $V/1.4$.*
- PHT across isolated MS can be **between 90 and 383 msec.**

In stenotic mitral valves, there is a linear and inverse relationship between MVA and PHT.

The more severe the MS, the longer the PHT.

Hatle et al, Noninvasive assessment of AVPHT by doppler Ultrasound, Circulation 1979;60:1096-1104

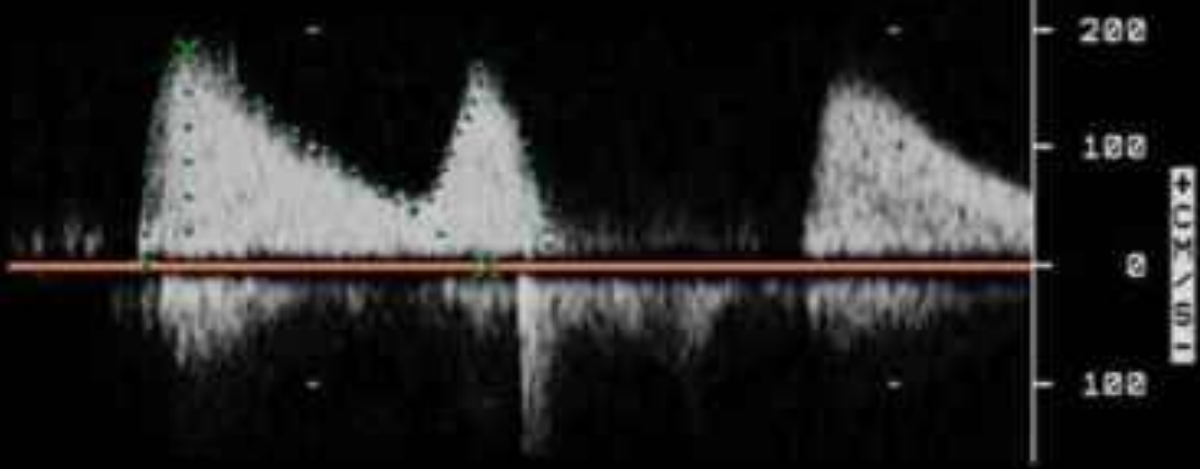- **Hatle** and colleagues proposed a derivation of MVA by using the empirical formula

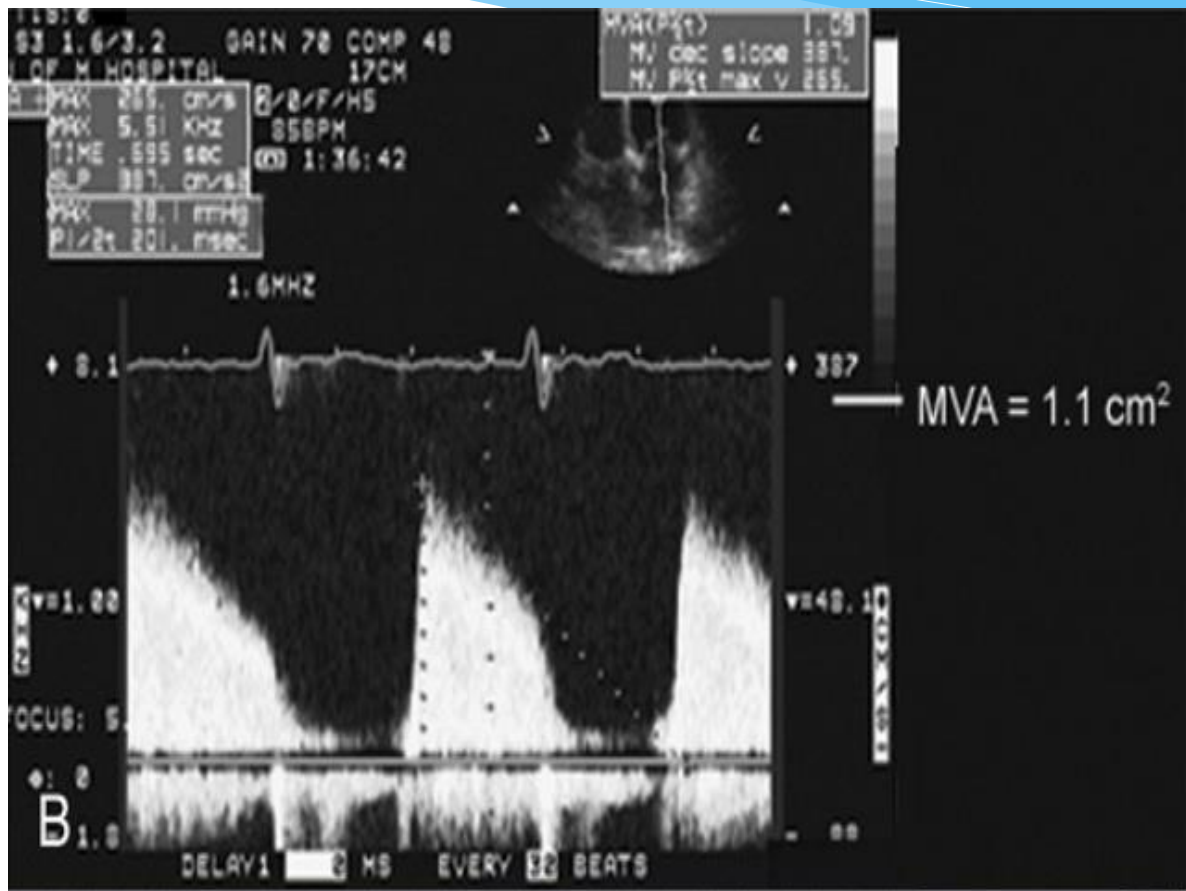
$$\text{MVA} = 220/\text{PHT}$$

- *The PHT can also be calculated by multiplying the deceleration time (time required for the peak velocity to decrease to the zero baseline) by 0.29.*
- PHT is **directly proportional** to left atrial and ventricular chamber compliance and the square root of the initial peak gradient.

Pressure Half-Time (milliseconds)

Mild 110 - 147 msec
Moderate 148 - 219 msec
Severe ≥ 220 msec





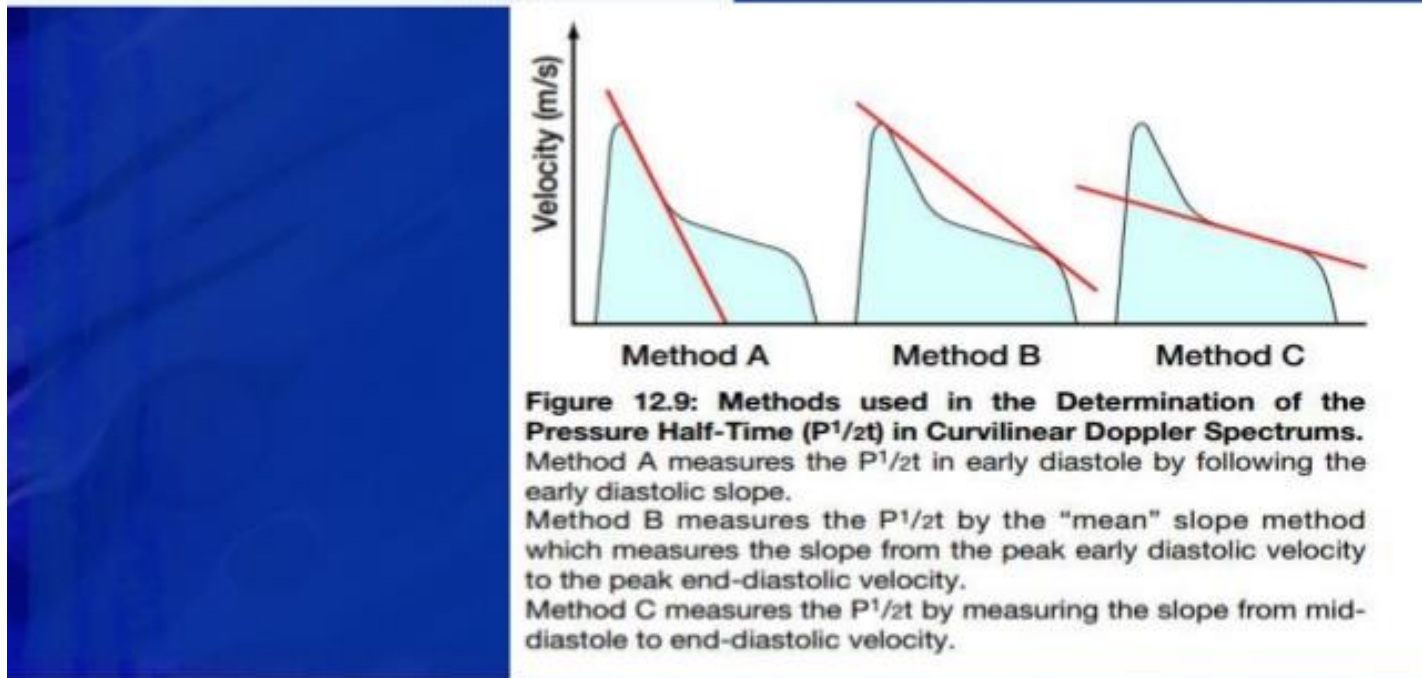
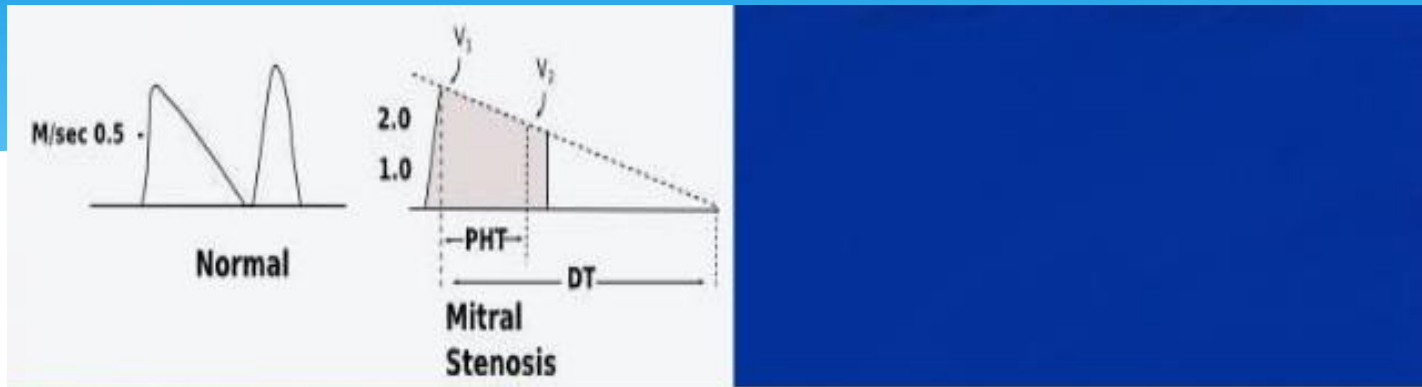


Figure 12.9: Methods used in the Determination of the Pressure Half-Time ($P^{1/2}t$) in Curvilinear Doppler Spectrums. Method A measures the $P^{1/2}t$ in early diastole by following the early diastolic slope. Method B measures the $P^{1/2}t$ by the "mean" slope method which measures the slope from the peak early diastolic velocity to the peak end-diastolic velocity. Method C measures the $P^{1/2}t$ by measuring the slope from mid-diastole to end-diastolic velocity.

Ecuatia de continuitate

For example, calculation of the mitral valve area can be derived from the stroke volume through the LVOT and the VTI across the mitral valve (Figure 12.2 and Practical Example 12.2). This assumes that the stroke volume through the stenotic mitral valve is equal to the stroke volume within the LVOT. As the stroke volume is a product of the CSA and the VTI, the stenotic mitral valve area (MVA) can then be derived by the application of the following equation:

(Equation 12.8)

$$MVA = \frac{CSA_{LVOT} \times VTI_{LVOT}}{VTI_{MV}}$$

where MVA = mitral valve area (cm²)
CSA_{LVOT} = cross-sectional area of left ventricular outflow tract (cm²)
VTI_{LVOT} = velocity time integral through the left ventricular outflow tract (cm)
VTI_{MV} = velocity time integral across the mitral valve (cm)

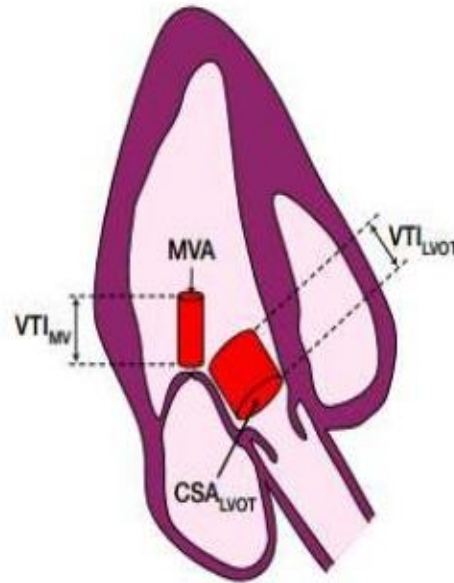


Figure 12.2: Calculation of the Mitral Valve Area by the Continuity Equation.

Using the continuity principle it is assumed that the stroke volume through the stenotic mitral valve (SV_{MV}) is equal to the stroke volume within the LVOT (SV_{LVOT}). As the stroke volume is a product of the integrated velocity over time (VTI) and the cross-sectional area (CSA), CSA_{LVOT} × VTI_{LVOT} = MVA × VTI_{MV}. If the CSA_{LVOT}, VTI_{LVOT} and VTI_{MV} can be measured, then the stenotic mitral valve area (MVA) can then be derived using Equation 12.8.

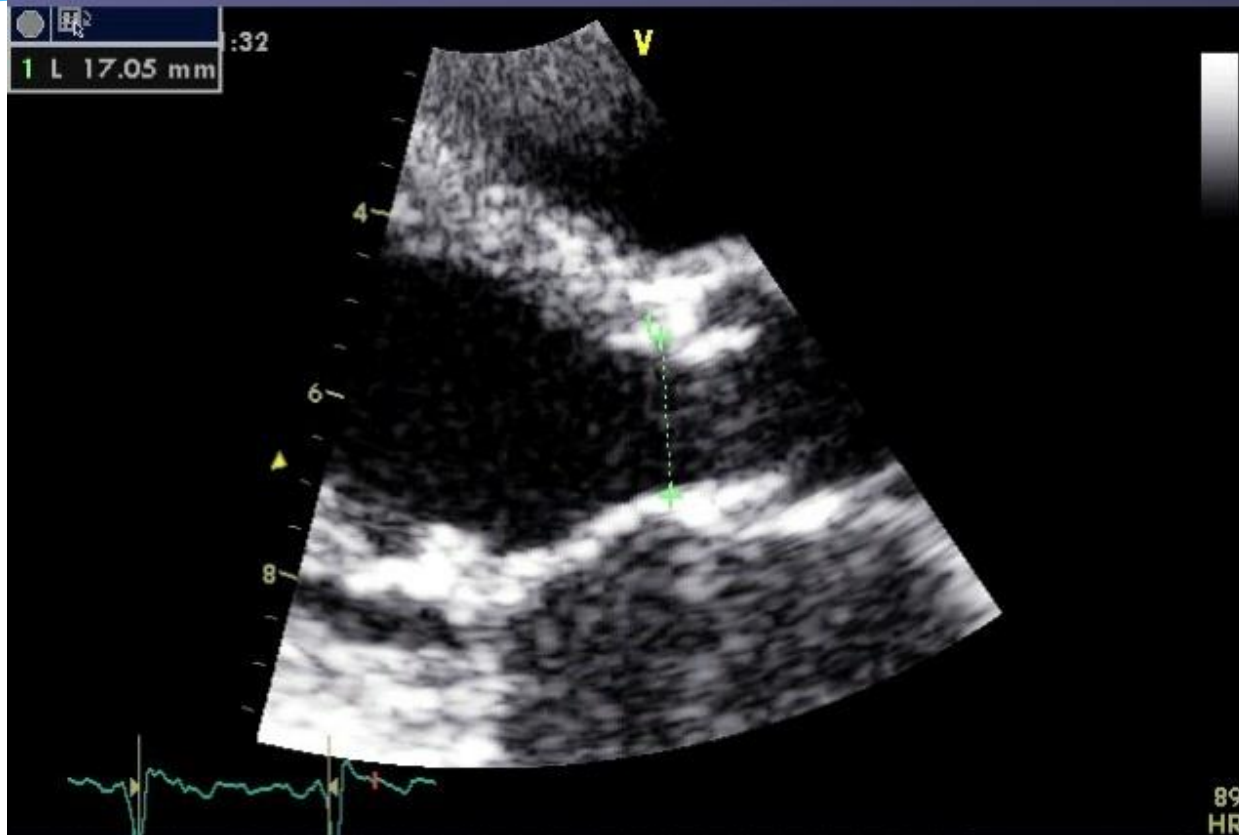
Continuity equation

So according to the conservation of flow:
Flow across mitral valve = flow across LVOT

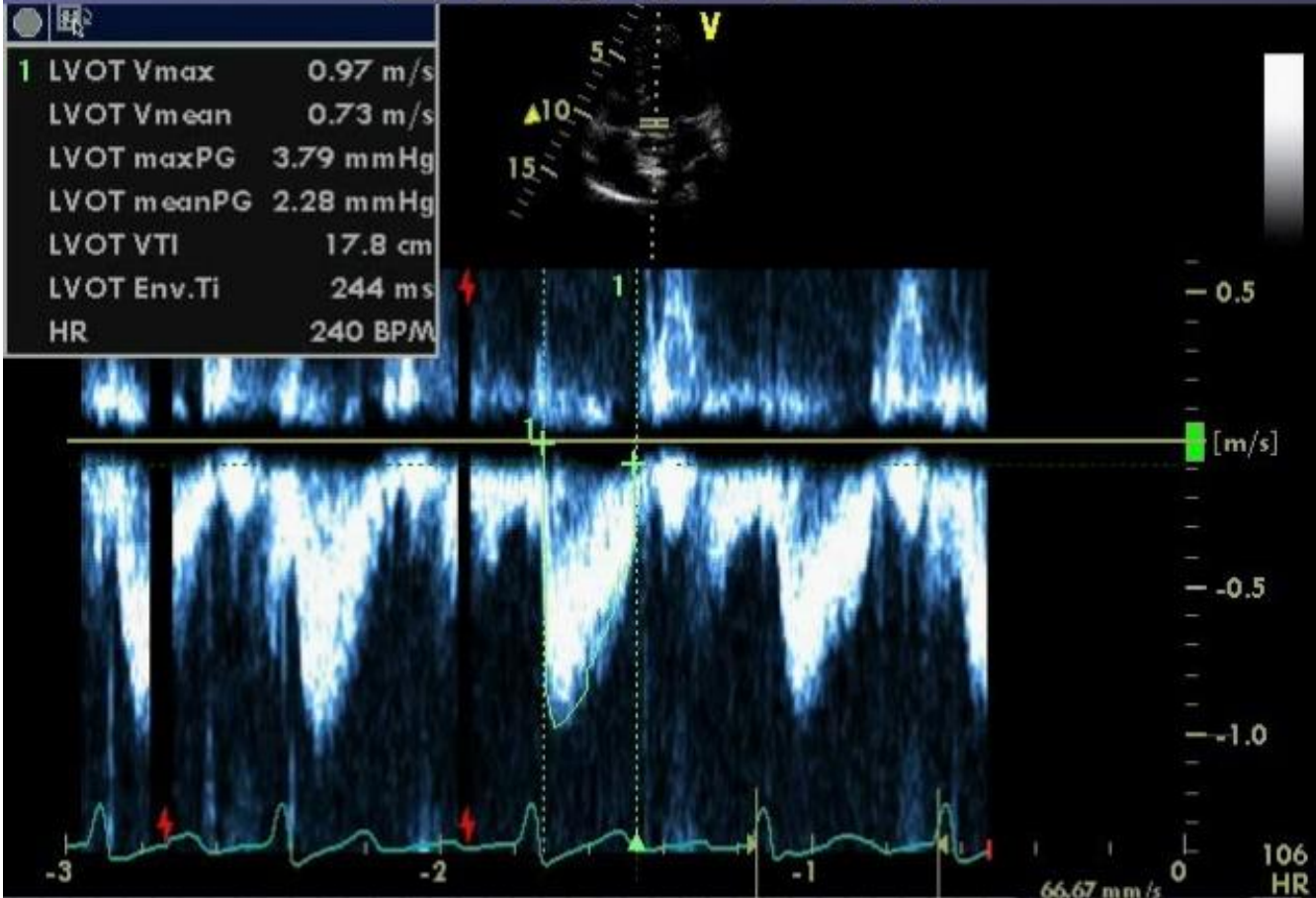
$$MVA \times MV_{VTI} = LVOT \times LVOT_{VTI}$$

$$MVA = \frac{LVOT \times LVOT_{VTI}}{MV_{VTI}}$$

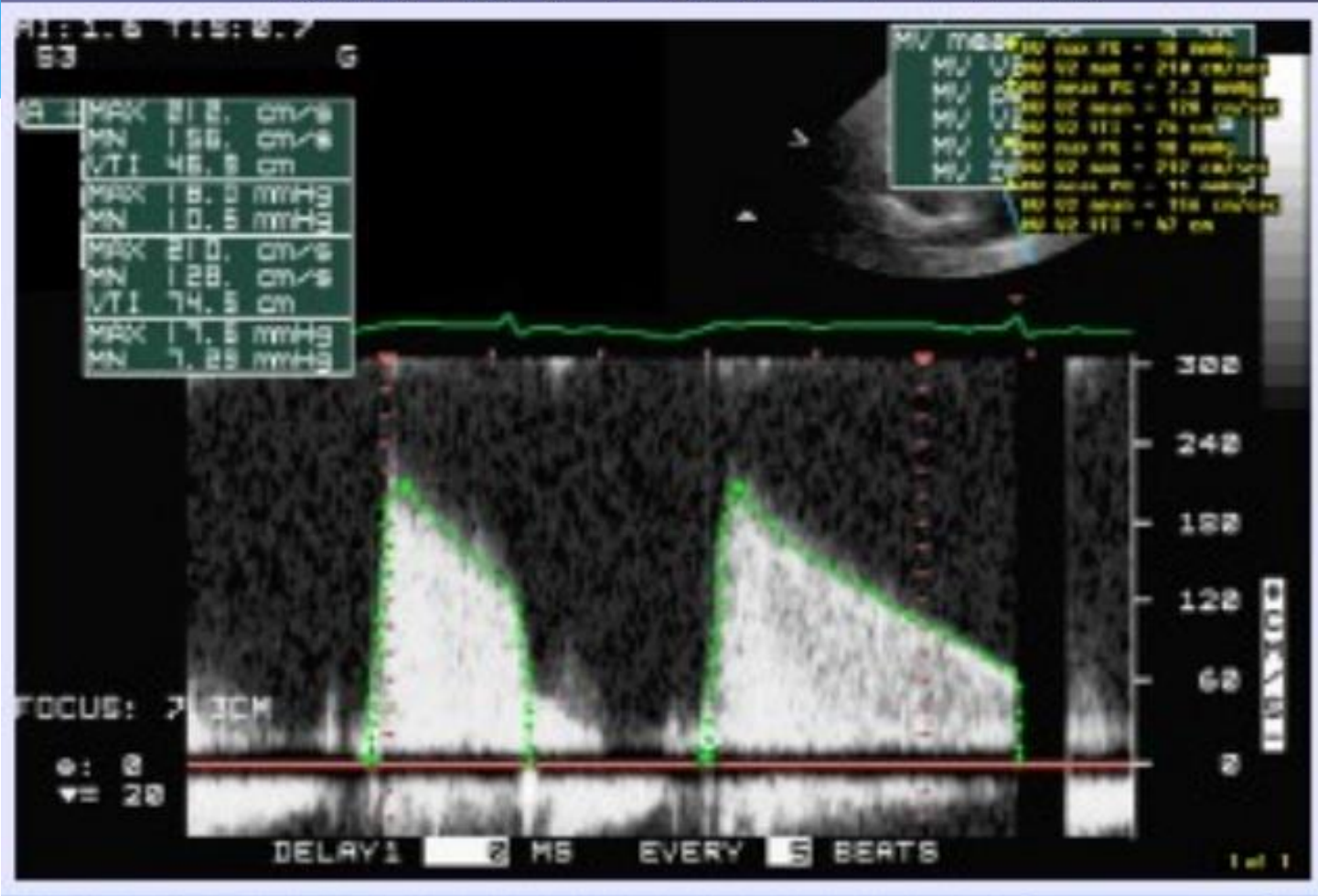
LVOT DIAMETER



LVOT VTI



MITRAL VALVE VTI



Limitation

- Cannot use continuity equation to calculate the valve area in the presence of significant mitral regurgitation (overestimation) or aortic regurgitation (underestimation)

Mitral Stenosis: Role of Echocardiography

- Diagnosis of Mitral Stenosis
- Assessment of hemodynamic severity
 - mean gradient, mitral valve area, pulmonary artery pressure
- Assessment of right ventricular size and function.
- Assessment of valve morphology to determine suitability for percutaneous mitral balloon valvuloplasty
- Diagnosis and assessment of concomitant valvular lesions
- Reevaluation of patients with known MS with changing symptoms or signs.
- F/U of asymptomatic patients with mod-severe MS

Trtament farmacologic

- * Diuretice
- * Profilaxia endocarditei infectioase
- * Tratamenteul aritmiilor

Tratament chirurgical

- * Prima optiune ramane plastia valvulara
- * Protezarea valvulara la varsta frageda impune, in evolutie, minim o reinterventie pentru schimbarea protezei (adaptata noilor dimensiuni ale copilului)
- * Se folosesc valve aortice bidisc de generatie noua (cu dimensiuni incepand cu 17 mm)

Complicatii la distanta la copilul cu stenoza mitrala operata

- * Complicatiile tratamentului anticoagulant cronic (obligatoriu toata viata dupa implantarea protezei metalice)
- * Endocardita infectioasa (necesita profilaxie permanenta)
- * Disfunctionalitatea protezei (trombi/vegetatii)
- * Mismatch-ul protezei (odata cu cresterea copilului)

Ce am invatat?

- * 1. Am aprofundat anatomia VM
- * 2. Evaluarea stenozei mitrale
 - * -gradient transmitral mediu
 - * -PHT



INSUFICIENTA MITRALA

INSUFICIENTA MITRALA -ETIOLOGIE

Inel mitral

- calcificari

Valve

- Degenerare mixomatoasa
- Boala reumatica
- Endocardita
- SAM (hypertrophic cardiomyopathy)
- Cleft
- Tesut valvular accesori

Cordaje

- Ruptura (idiopatica)
- Endocardita

Mm papilari

- Disfunctie sau ruptura

Ventricul stang

- Dilatare

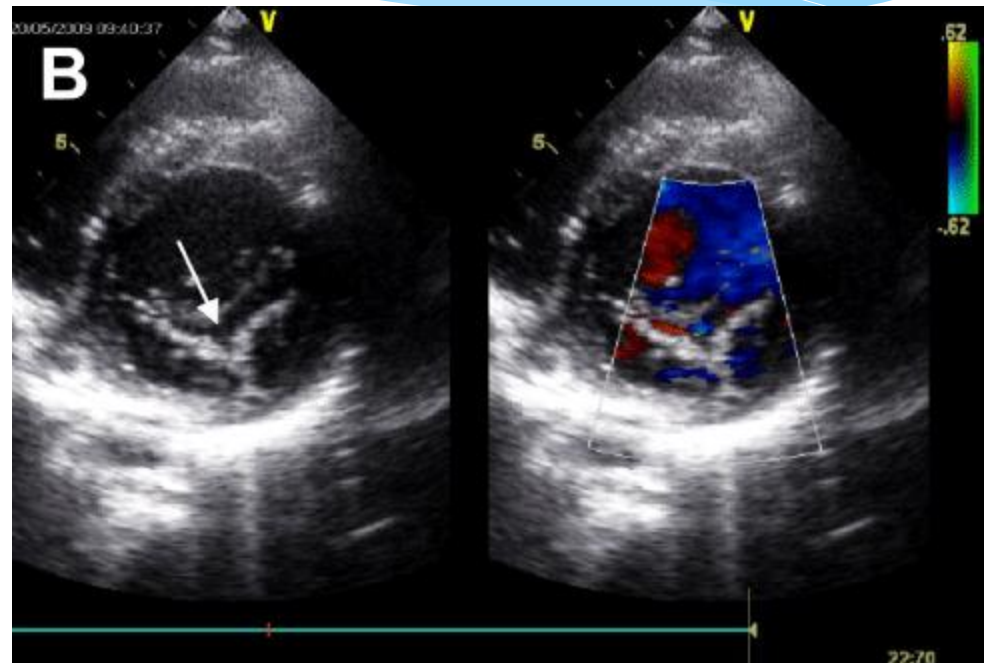
Regurgitarea mitrala cu anatomie normala

Se asociaza cu situatii de supraincarcare de volum a VS (DSV larg, CAP larg)

- * Fiziopatologic: dilatare de inel posterior ca efect al supraincarcarii de volum si secundar cordajul marginal se alungeste si creeaza prolaps al marginii libere a cuspei anterioare

1.Cleft de valva mitrala

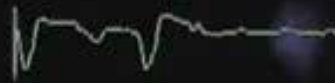
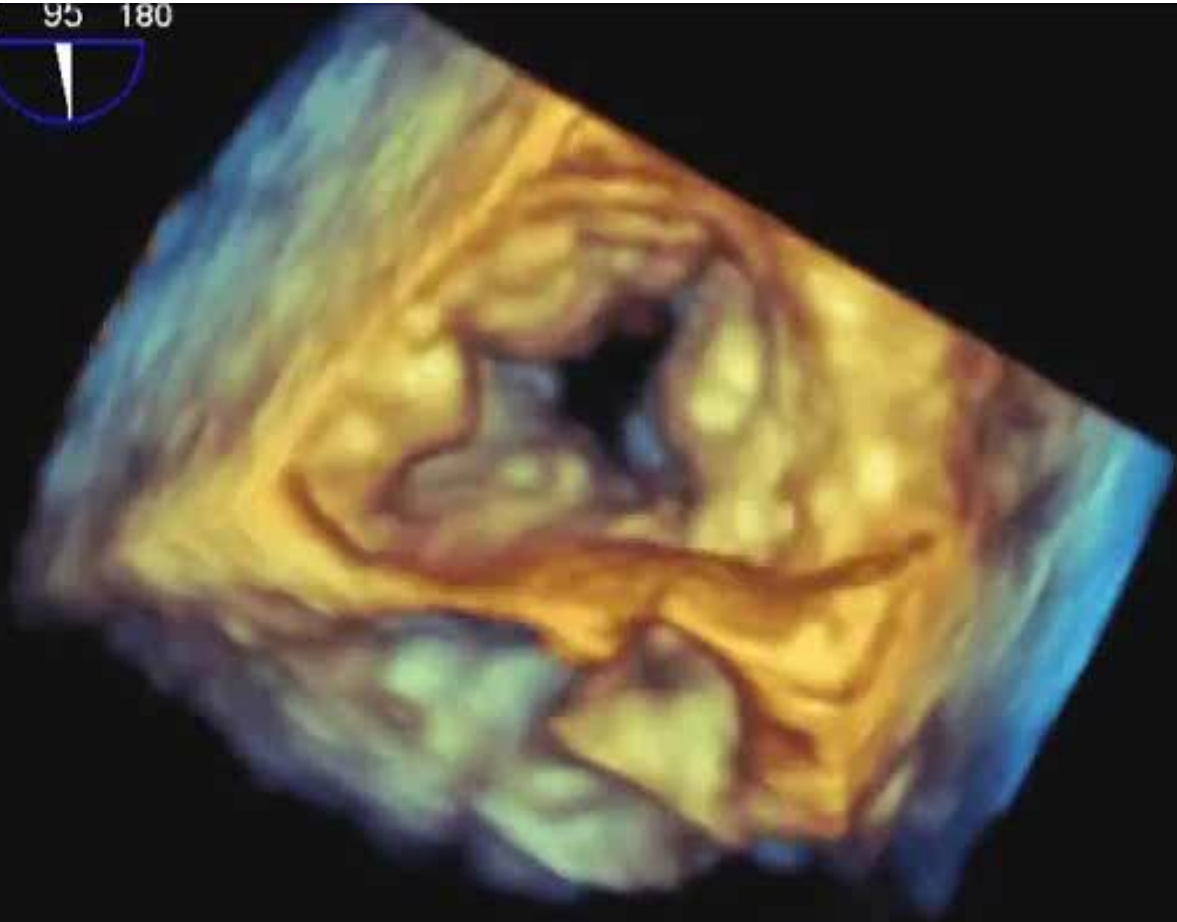
- * Ambii muschi papilari sunt normali
- * Rareori se asociaza cu un defect de tesut al valvei, defect secundar regurgitarii cronice prin cleft
- * Defectul nu este niciodata stenotic si poate genera doar regurgitare usoara timp indelungat



VR 20Hz 0 95 180
6cm



Live 3D
3D 44%
3D 40dB



99 bpm

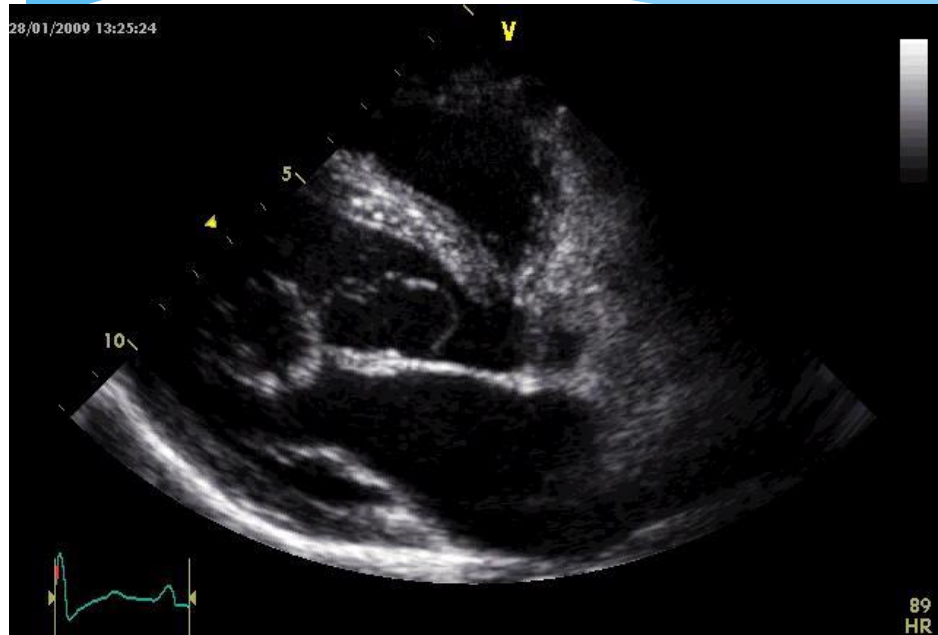
PHILIPS

Leziuni regurgitante

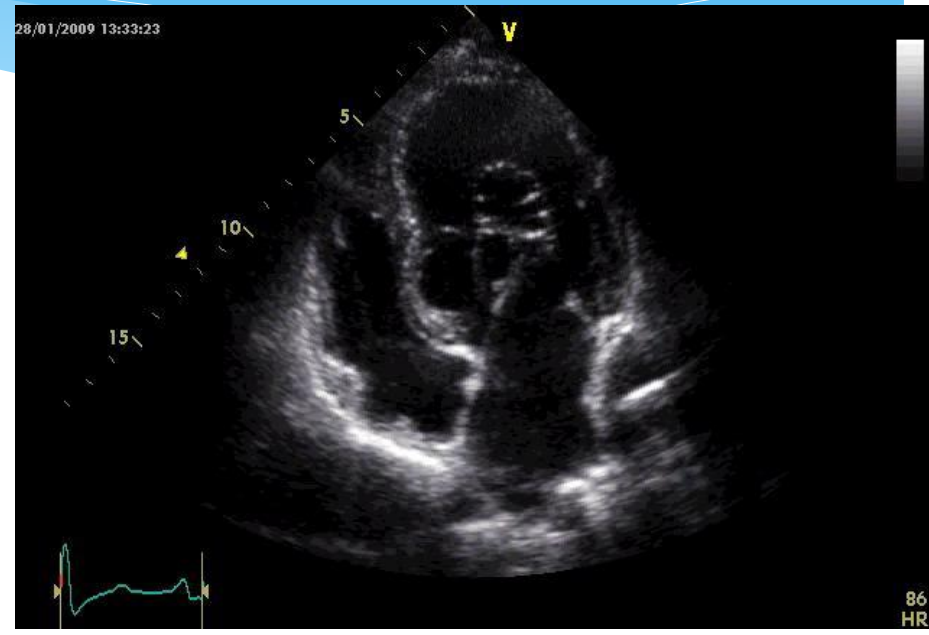
2. Tesut valvular accesoriu

- * În această anomalie spațiul dintre cordaje este umplut cu o rețea densă de țesut valvular.
- * Poate genera un gradient invers proporțional cu dimensiunea orificiului de perforare a acestui țesut
- * Când țesutul accesoriu este tras în CEVS, VM devine regurgitantă datorită tracțiunii exercitate de t. accesoriu asupra VMA
- * Obstrucția CEVS este leziunea predominantă în această patologie.

Tesut valvular accesor

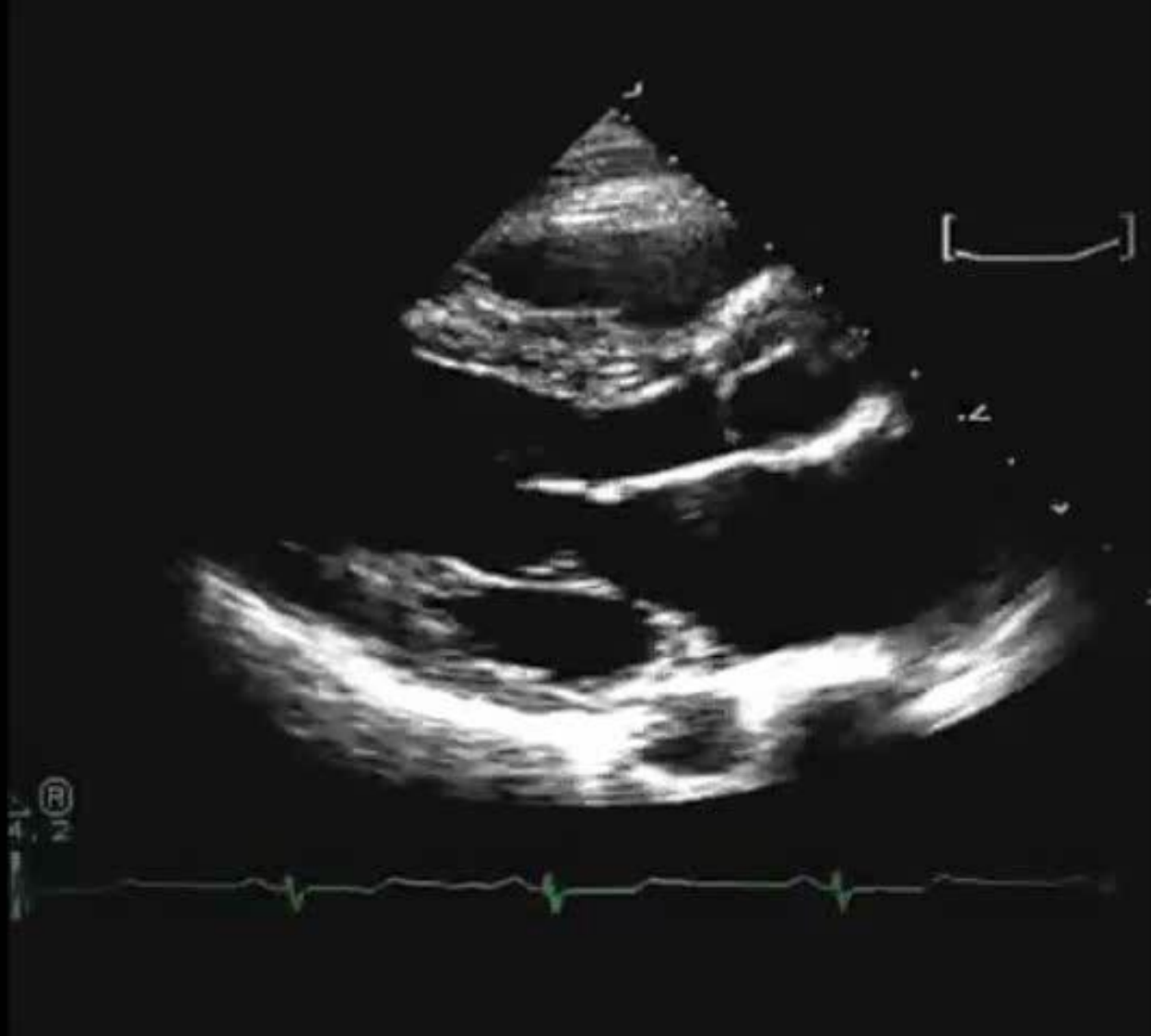


Parasternal ax lung



Apical 4 camere

SAM



SAM

MI: 1.1 TIS: 1.1

S3
29 OCT 10
14.59.10

medicaldump.com

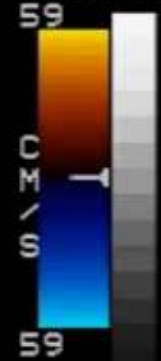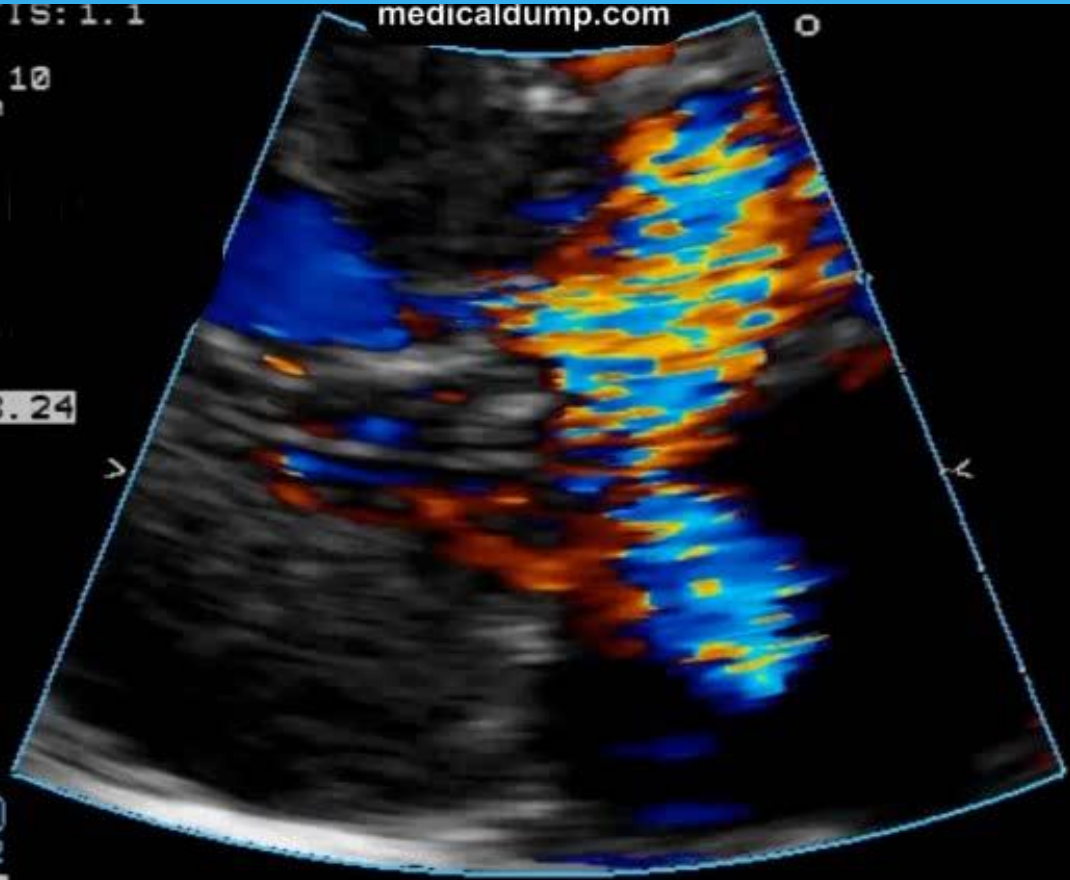
2.5MHz

04118.24

GAIN 63
COMP 57
78BPM

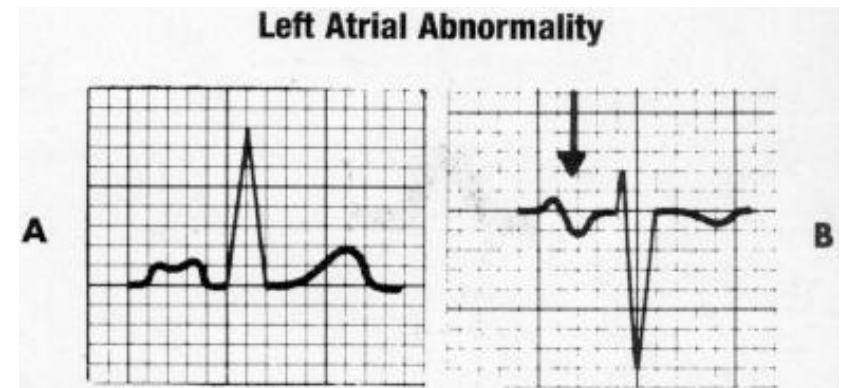
16CM
16HZ

T
P 1.6 3.2 R



Electrocardiograma in RM

- * Dilatare de AS (unda P bifida)
- * Suprasolicitare de volum VS (hipervoltaj QRS in precordiale)
- * Suprasolicitare de VD cand se instaleaza HTP
- * La copii, ritmul este aproape intotdeauna sinusal

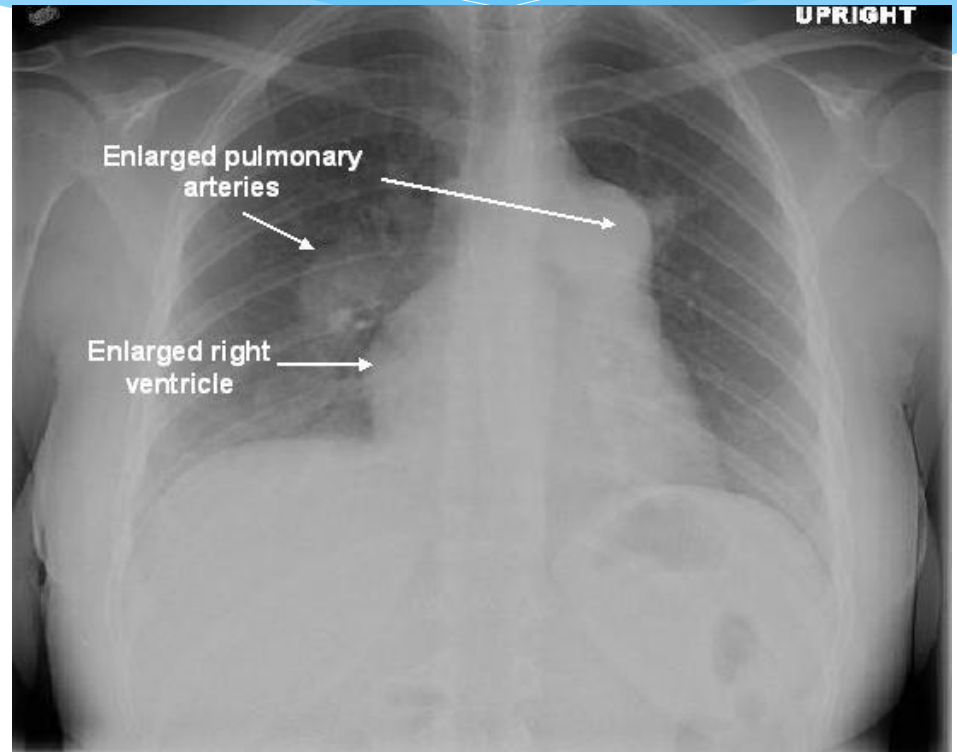


Simptomatologie si examen clinic

- * Dispnee de efort
- * Tahipnee
- * Infectii respiratorii recurente
- * Clinic:
 - * Suflu sistolic in focarul mitral
 - * Particular: suflu (mezo)telesistolic +/- click telesistolic in prolapsul de VM

Modalitati de diagnostic in patologia valvei mitrale (2)

- * Radiografia toracica:
 - * Frecvent - dilatare de AS (dublu contur la nivelul arcului inferior drept), mai frecvent in regurgitarea de VM decat in stenoza
 - * Variabil: contur largit al arterei pulmonare
 - * Dilatarea de VS (marirea arcului inferior stang cu apexul cordului sub linia diafragmului).



Ecocardiografia

- * Este obligatorie si esentiala
- * Aduce toate informatiile necesare diagnosticului anomaliei mitrale,
- * Poate cuantifica severitatea si sa ajute chirurgul in vederea alegerii tehnicii chirurgicale

Evaluarea regurgitarii mitrale (RM)- ecocardiografia –

- * Oferă informații legate de:
 - * etiologia RM,
 - * mecanismul de producere,
 - * gradul extinderii leziunii valvulare,
 - * posibilitatea de reparare a valvei
- * Secțiuni recomandate:
 - * Parasternal ax lung
 - * Parasternal ax scurt la nivelul VM și mușchilor papilari
 - * Apical 4C

Ecocardiografia 2 d

- * Precizarea mecanismului RM este extrem de importanta in practica, mai ales in vederea corectiei chirurgicale.
- * In practica se foloseste clasificarea Carpentier care face posibila clasificarea patologiei VM in functie de miscarea cuspelor in 3 tipuri- clasificarea Carpentier
 - * aduce date suplimentare chirurgului

Ecocardiografia 2 d

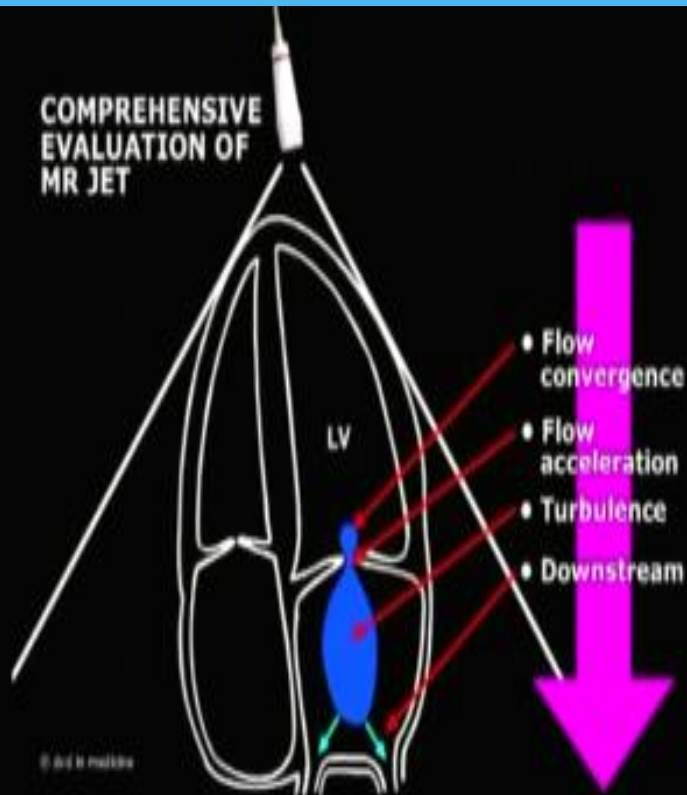
- * Clasificarea Carpentier:
 - * Tipul I: valve cu mobilitate normala (dilatare de inel mitral, perforarea unei cuspe)
 - * Tipul II: valve cu mobilitate excesiva (prolaps, ruptura de cordaje)
 - * Tipul III: valve cu miscare restrictionata
 - * III A: miscare restrictionata atat in sistolo cat si in diastola prin scurtarea cordajelor si/sau ingrosarea cuspelor (reumatismal)
 - * III B: miscare restrictionata in sistola (ischemica)



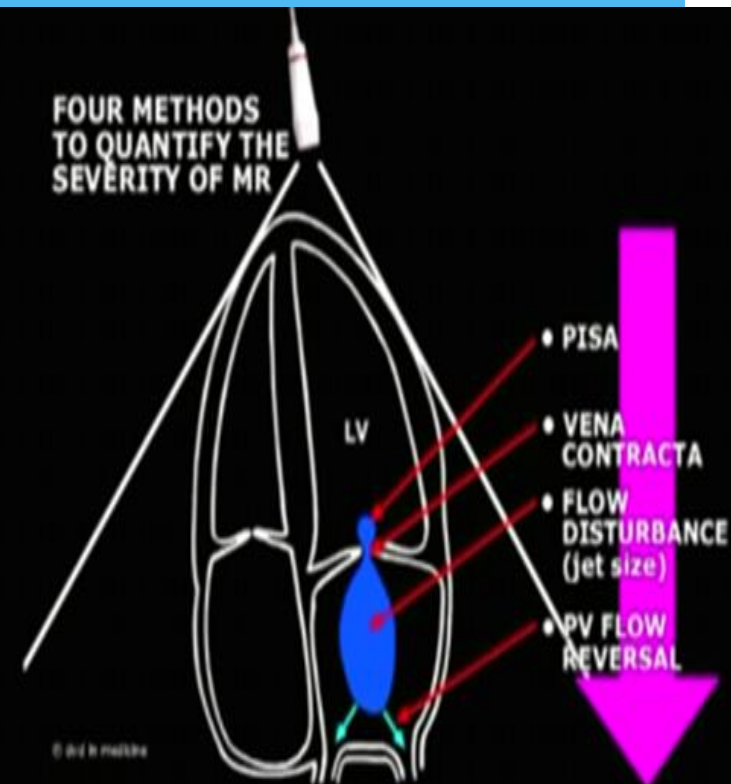
EVALUARE DOPPLER INSUFICIENTA MITRALA

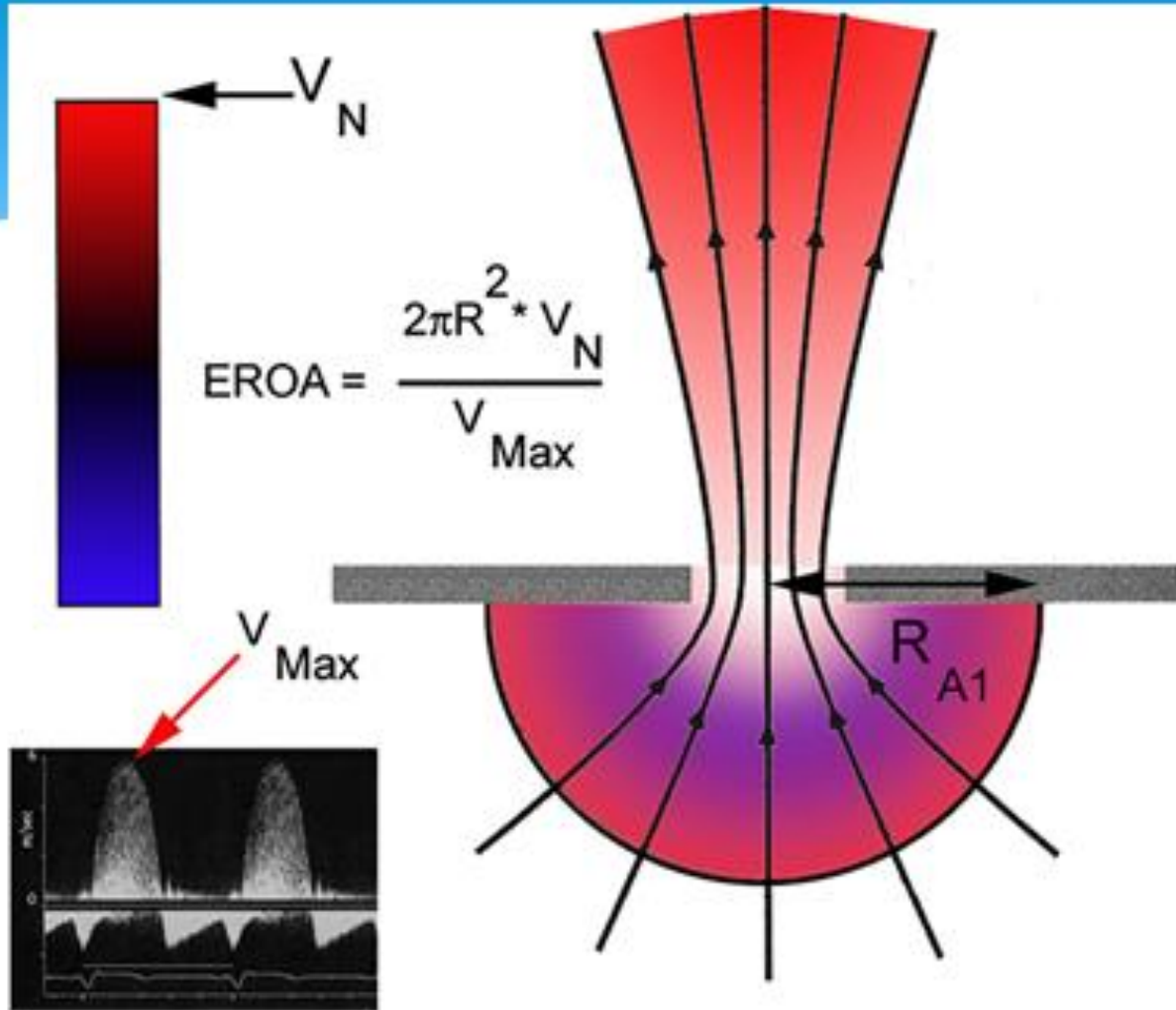
Parametri Doppler de evaluare a severitatii IM

COMPREHENSIVE EVALUATION OF MR JET



FOUR METHODS TO QUANTIFY THE SEVERITY OF MR

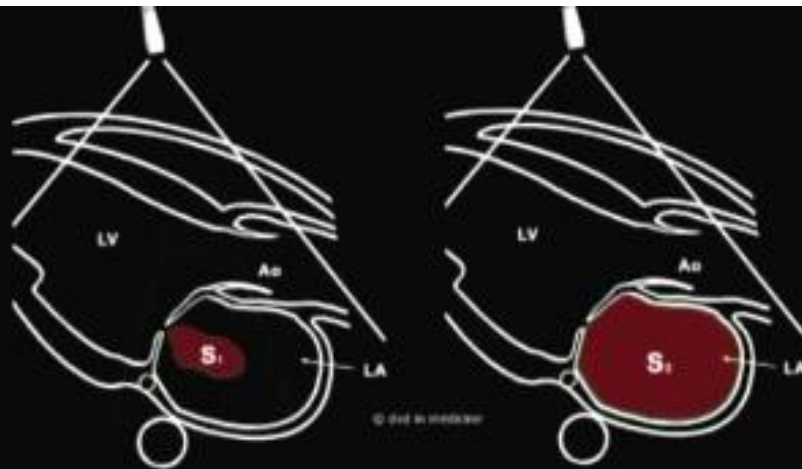




Aria jetului de RM

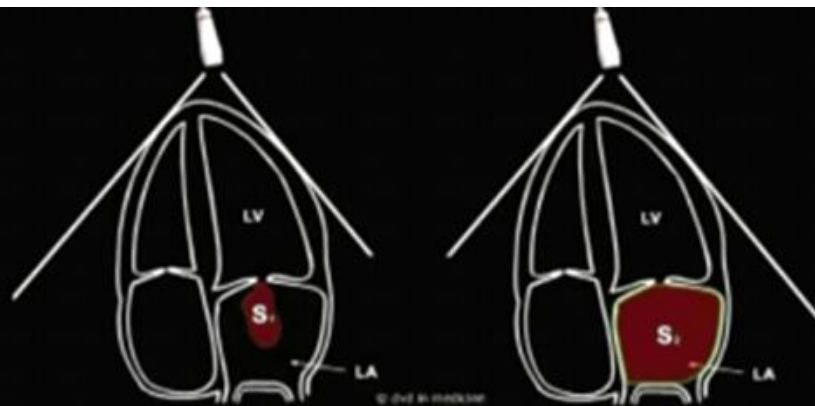
THE GRADING OF MITRAL REGURGITATION (color jet area)

Mild MR	< 20% of total LA area (or a maximal jet area < 4,0 cm ²)
Moderate MR	20-40% of total LA area (or a maximal jet area 4-10 cm ²)
Severe MR	> 40% of total LA area (or a maximal jet area > 10 cm ²)



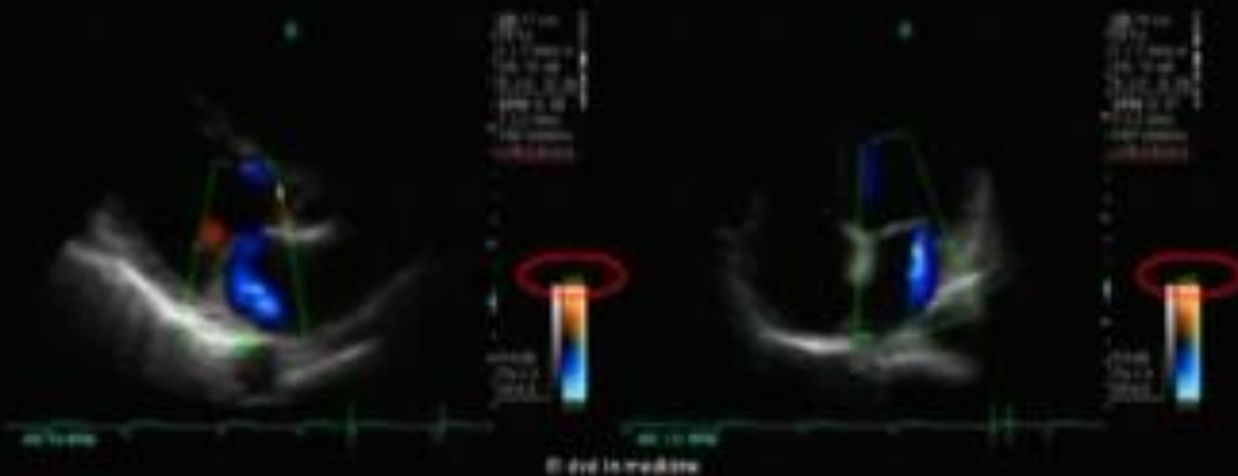
MEASURING OF COLOR JET AREA (PLAX)

$$\frac{S_1}{S_2} \times 100\% = \% \text{ of total LA area}$$



**MEASURING OF COLOR JET AREA
(Apical 4-Chamber)**

$$\frac{S_1}{S_2} \times 100\% = \% \text{ of total LA area}$$



PLAX

four-chamber view

Color jet area (moderate MR)

PLAX

ZD: 26 cm
IS 1:1
F: 1.7 MHz H
DR: 70 dB
R: 2.0 G: 01
CFM 0: 61
F: 2.2 MHz
PRF: 2600Hz
LVR: 2.9cm/s

P: 0dB
Tis: 1.3
Mt: 0.9

0.61
0.63

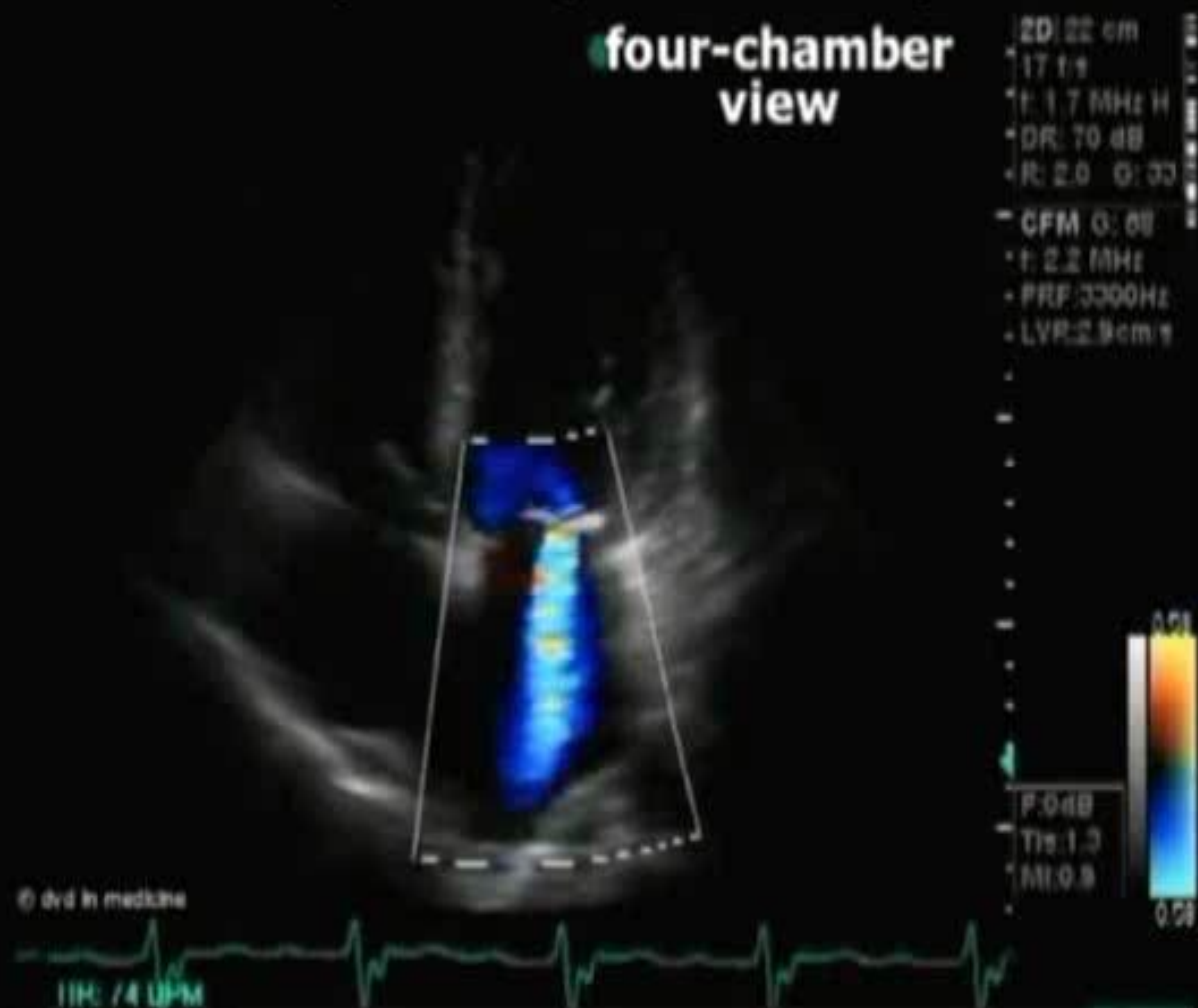
© dnd in medicine

118: 1/1 UPM

Patient A

Color jet area (moderate MR)

four-chamber view



Patient A

Vena contracta


VENA CONTRACTA WIDTH. GRADING OF MITRAL REGURGITATION

Mild MR	< 0,3 cm
Moderate MR	0,3 – 0,69 cm
Severe MR	> 0,7 cm

2D: 20 cm
40 1:1
F: 1.7 MHz H
DR: 70 dB
R: 2.0 0:31

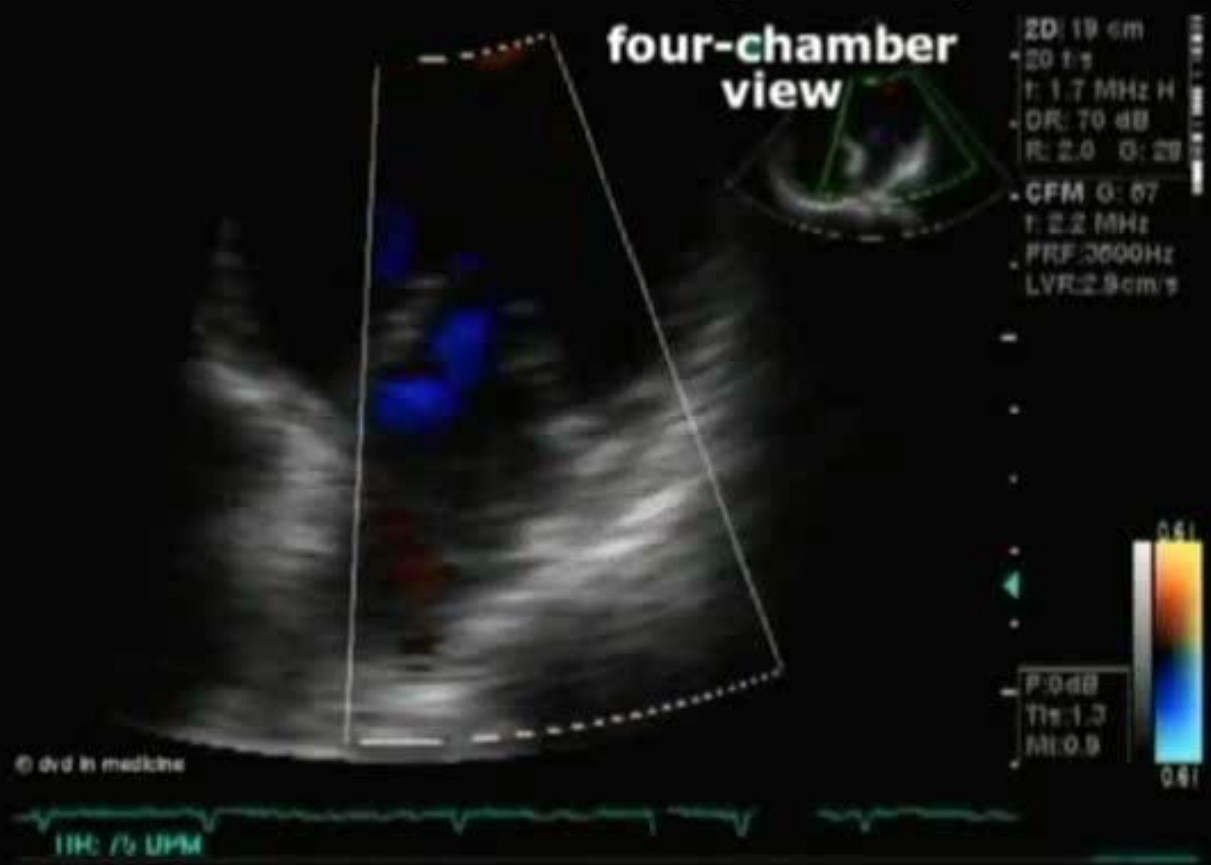
P 0.40
T1: 1.0
DR: 1.0

110/72 BPM



Vena contracta width (mild MR)

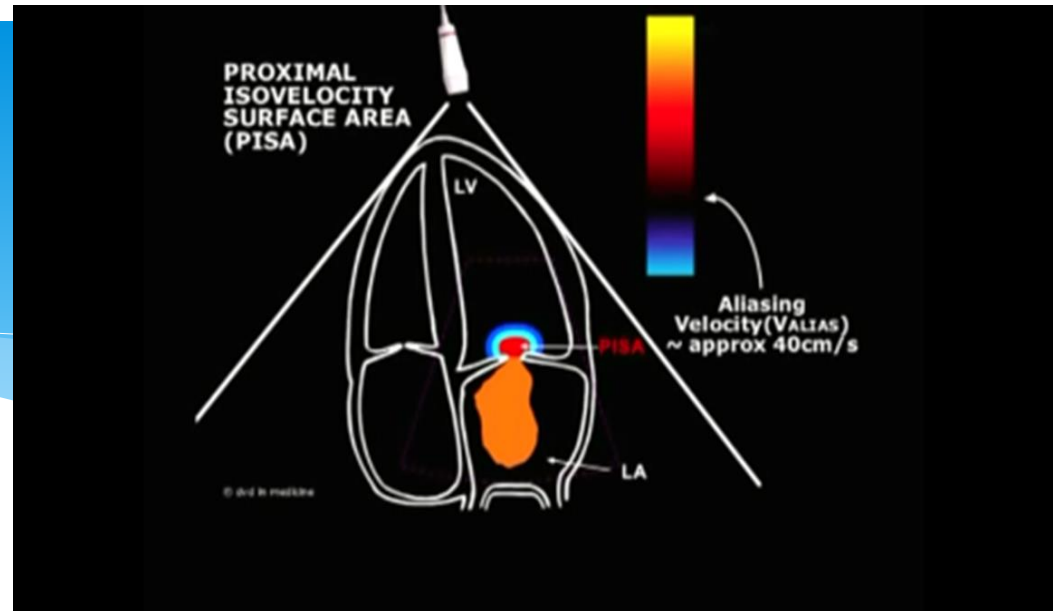
four-chamber view

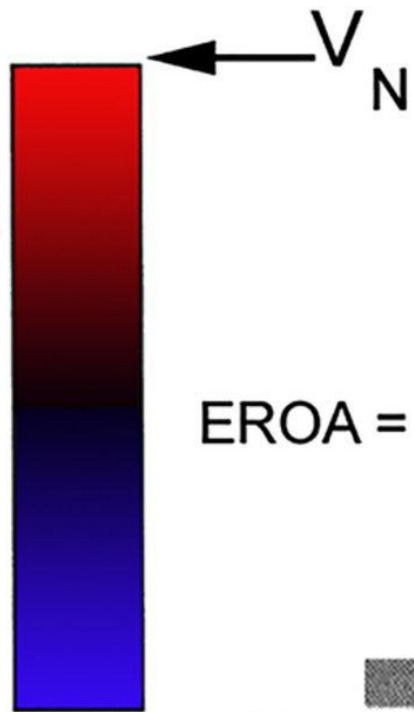


Patient E

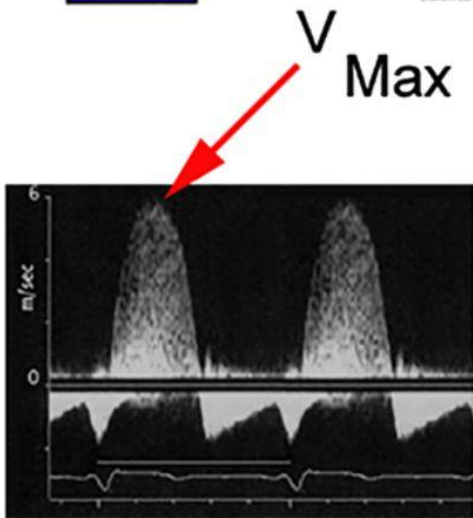
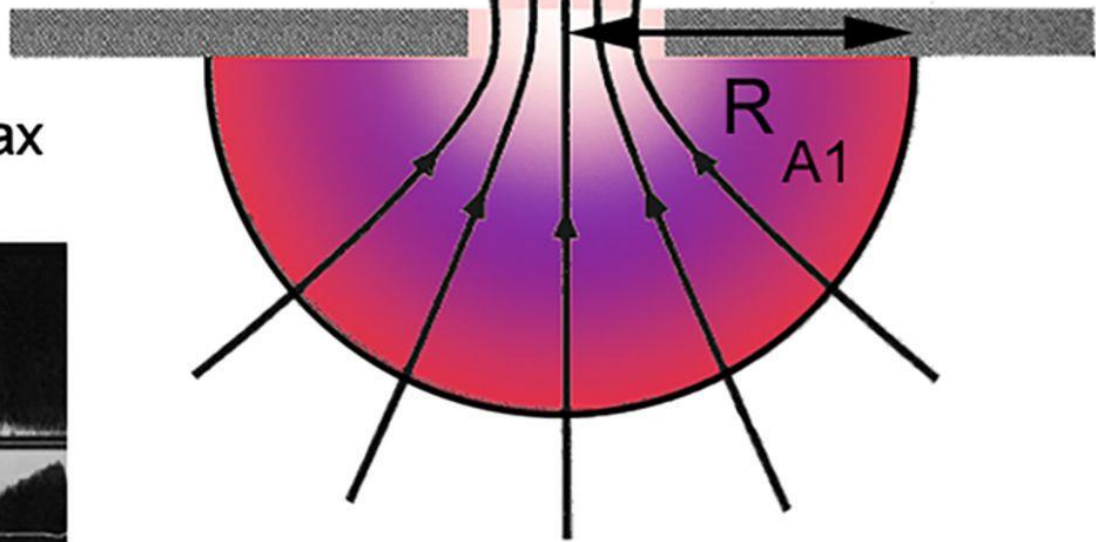
Proximal Isovelocity Surface Area

- * Ajuta la estimarea orificiului efectiv de regurgitare ERO



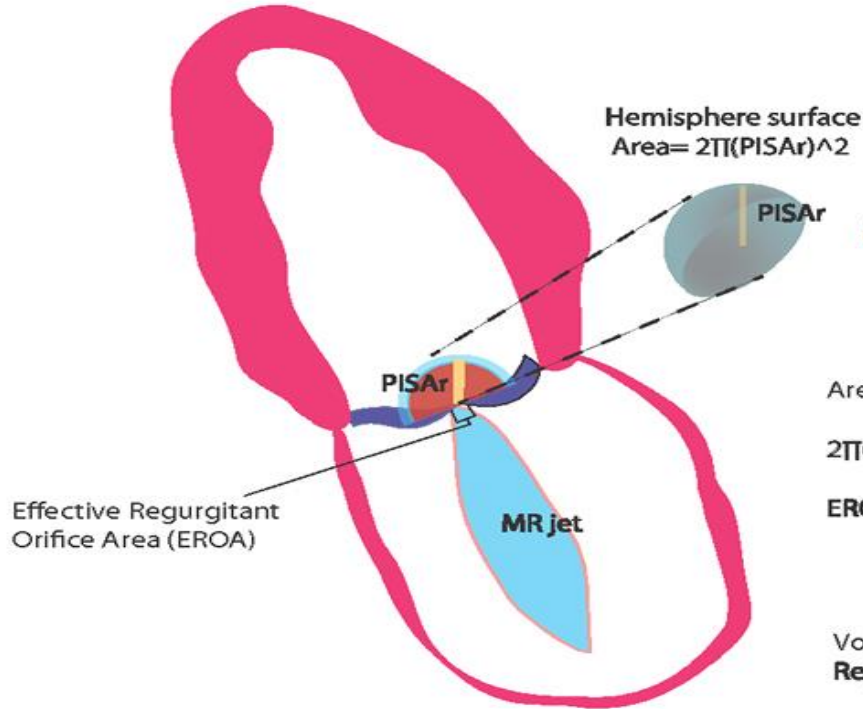


$$EROA = \frac{2\pi R^2 * V_N}{V_{Max}}$$



The PISA Method for Quantification of Mitral Regurgitation

Color Doppler of MR jet in an Apical Window



$$\text{Area}_1 \times \text{Velocity}_1 = \text{Area}_2 \times \text{Velocity}_2$$

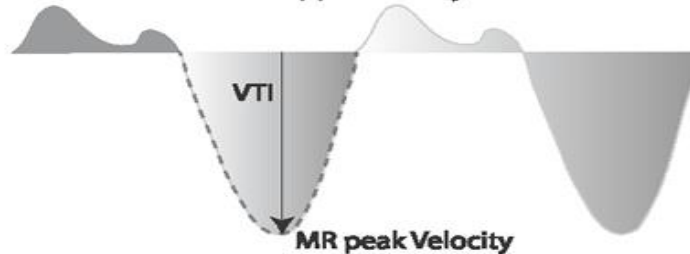
$$2\pi(\text{PISA}r)^2 * \text{Aliasing Velocity} = \text{EROA} \times \text{MR peak velocity}$$

$$\text{EROA} = \frac{2\pi(\text{PISA}r)^2 * \text{Aliasing Velocity}}{\text{MR peak velocity}}$$

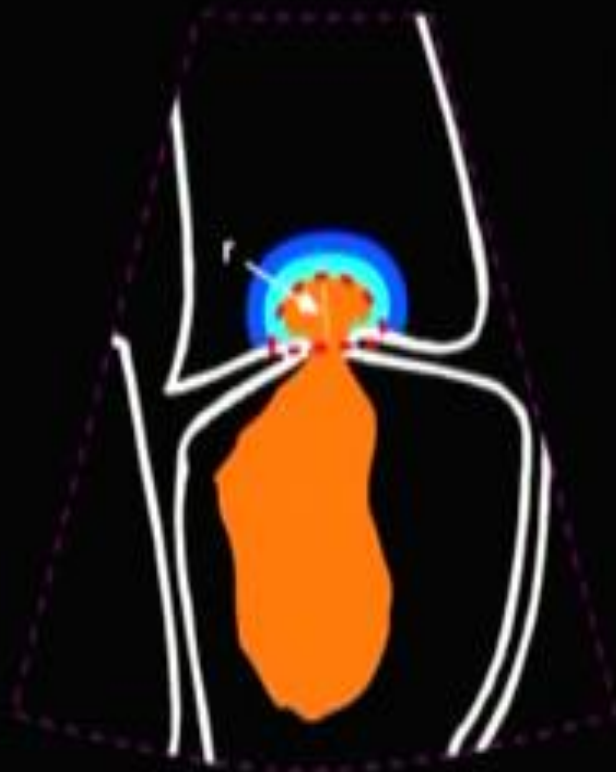
$$\text{Volume} = \text{Area} \times \text{VTI}$$

$$\text{Regurgitant Volume} = \text{EROA} \times \text{MR VTI}$$

Continuous Wave Doppler of MR jet



PISA radius (r)



- 40cm/s

© 2010 In Medicine

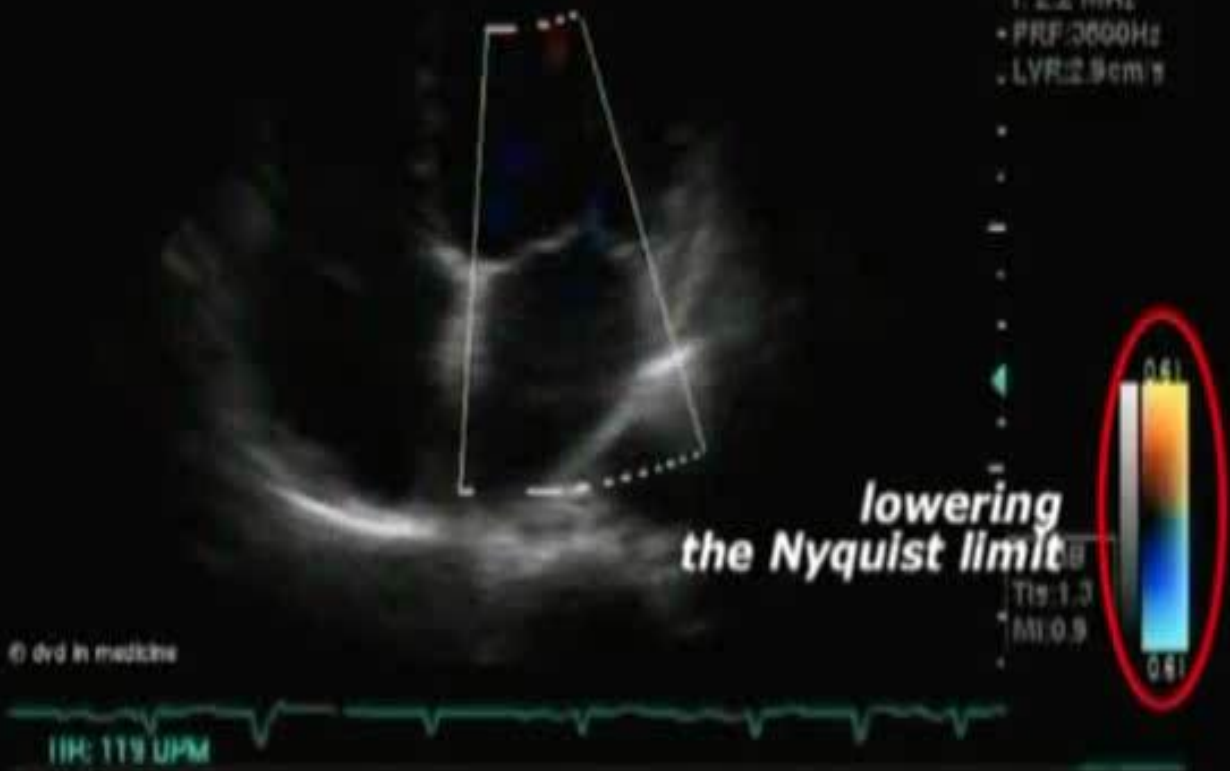
CALCULATION OF REGURGITANT FLOW RATE (PISA)

$$\text{Regurgitant flow rate (mL/s)} = 2\pi r^2 \times V_{\text{ALIAS}}$$

PISA (mild MR)

● four-chamber view

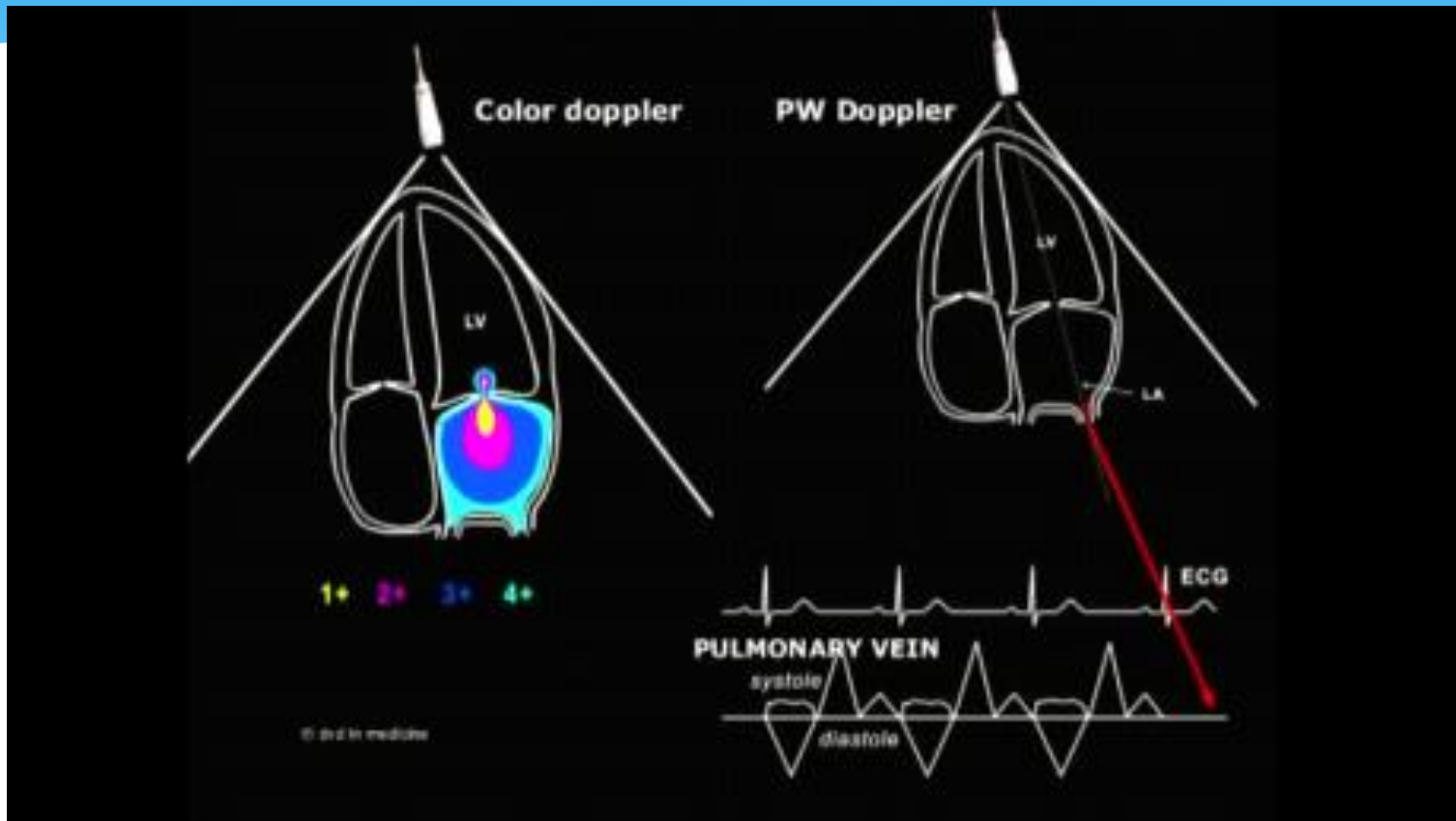
2D: 19 cm
18 1:5
f: 1.7 MHz H
DR: 70 dB
R: 2.0 G: 30
CPM 0: 67
f: 2.2 MHz
PRF: 3600Hz
LVR: 2.9 cm/s



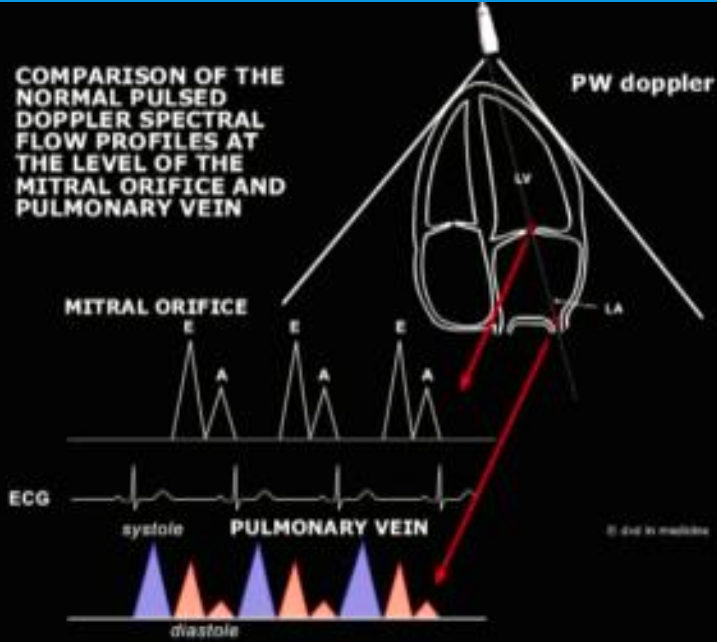
© dvd in medicine

Patient E

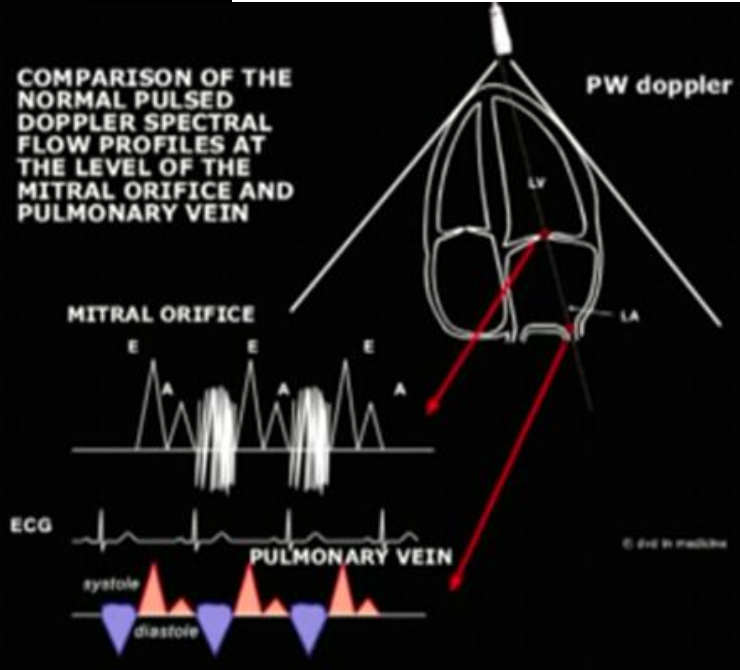
Flux veine pulmonare



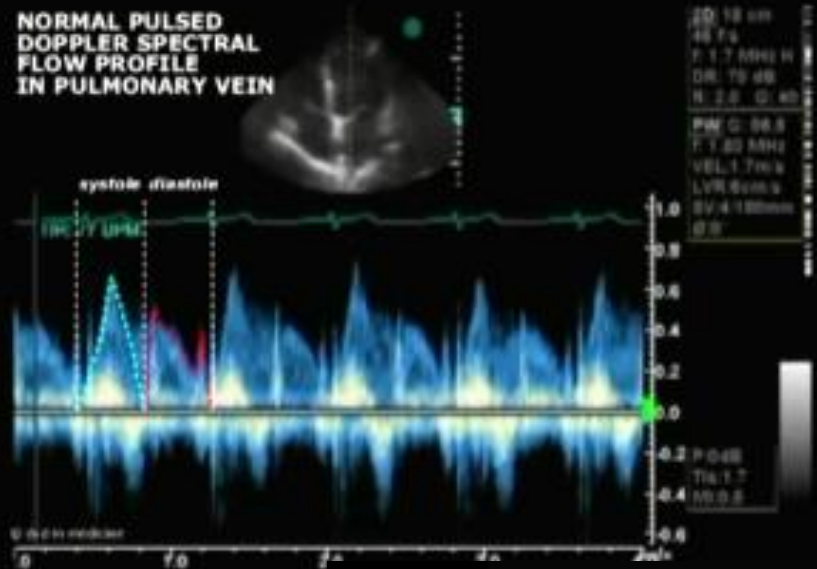
COMPARISON OF THE NORMAL PULSED DOPPLER SPECTRAL FLOW PROFILES AT THE LEVEL OF THE MITRAL ORIFICE AND PULMONARY VEIN



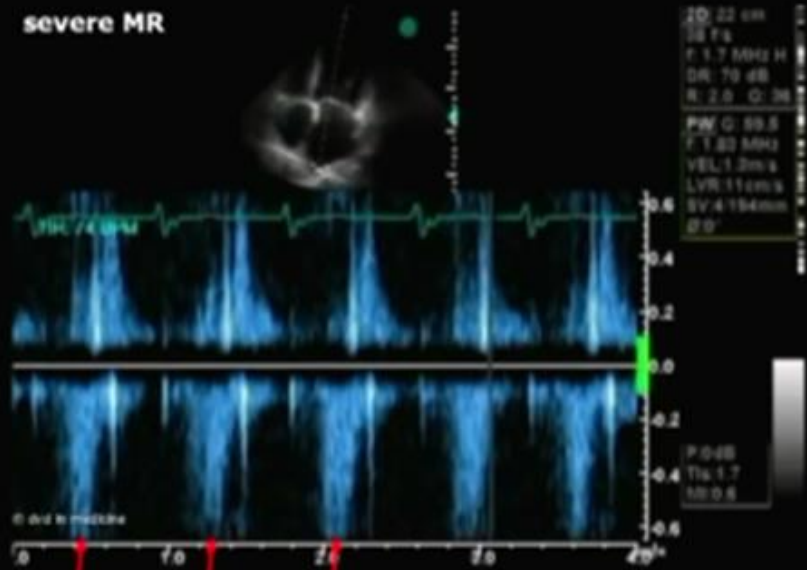
COMPARISON OF THE NORMAL PULSED DOPPLER SPECTRAL FLOW PROFILES AT THE LEVEL OF THE MITRAL ORIFICE AND PULMONARY VEIN



**NORMAL PULSED
DOPPLER SPECTRAL
FLOW PROFILE
IN PULMONARY VEIN**

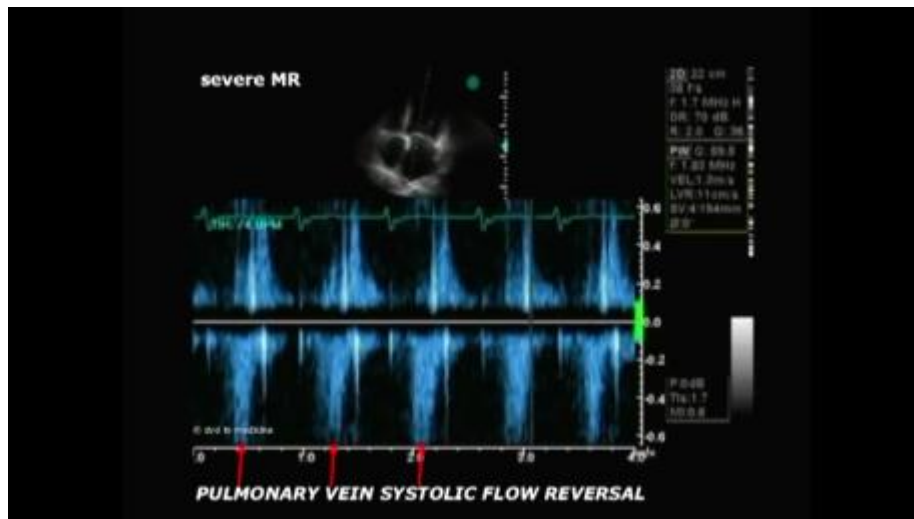


severe MR



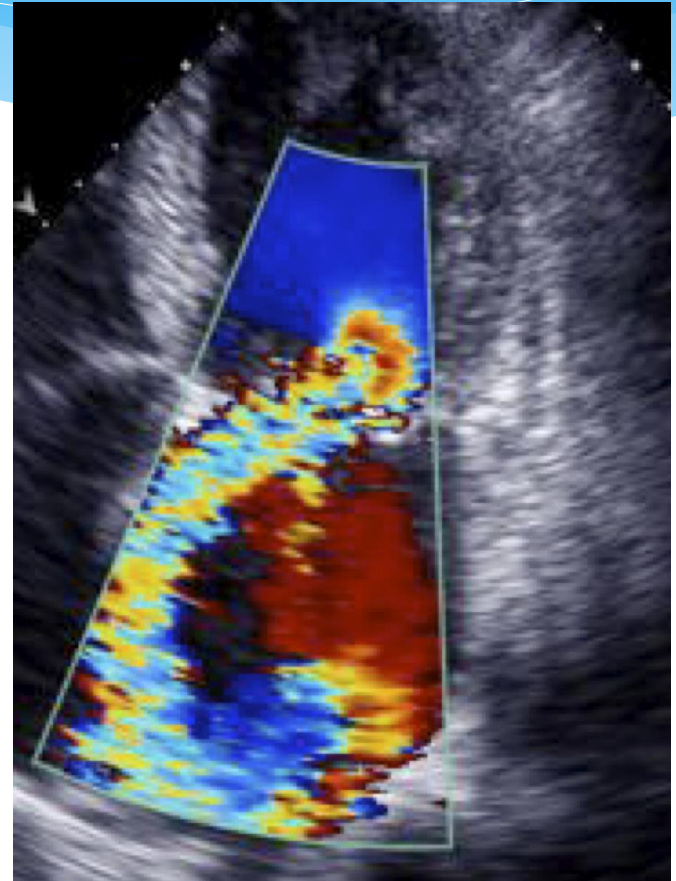
PULMONARY VEIN SYSTOLIC FLOW REVERSAL





Ecocardiografia doppler color(4)

- * Efectul Coanda: tendinta unui jet de fluid de a adera la o suprafata situata in proximitatea jetului.
- * Aplicatia: directionarea jetului de RM catre unul din peretii AS, astfel suprafata jetului pare mai mica decat daca ar fi central- subestimarea severitatii RM



Criteria ecocardiografice pentru SM severa

- * Morfologia valvei: flail/ ruptura de muschi papilar sau perforatie
- * Jetul de regurgitare mitrala (Doppler color): foarte mare, central sau excentric, care adera pe peretele AS si se rasuceste in AS ajungand pe peretele posterior al acestuia
- * Zona mare de convergenta proximala a fluxului
- * Anvelopa Doppler continuu la nivelul jetului de regurgitare: semnal cu intensitate mare forma triunghiulara a anvelopei.
- * Criteria indirecte: dilatare AS, VS, disfunctie VS.

Tratament medical

- * Trebuie sa fie maximal atunci cand inelul este prea mic pentru implantarea de proteza mitrala in pozitie anatomica (in vedrea amanarii momentului chirurgical)
- * IEC, diuretice
- * Profilaxia endocarditei infectioase

Tratament chirurgical(2)

- * Inel mitral ingust:
 - * Nou-nascut: 18-19 mm, interventia chirurgicala foarte riscanta, se prefera amanarea interventie cat se poate de mult prin tratament medical agresiv
- * Inel mitral intermediar:
 - * > 19 mm dar mai mic decat dimensiunea de adult
 - * Inlocuirea valvulara se poate realiza in conditii de siguranta, in pozitie anatomica
 - * Situatie frecventa la pacientii intre 1-12 ani, de regula se poate temporiza interventia chirurgicala timp indelungat (pana la cativa ani); in caz de regurgitare severa se monitorizeaza presiunea pulmonara si functia ventriculara
- * Inel mitral larg = mai mare de 30 mm la sexul feminin si mai mare de 32 mm la sexul masculin

Complicatii postoperatorii la distanta in corectia chirurgicala a VM

- * Complicatiile tratamentului anticoagulant cronic (obligatoriu toata viata dupa implantarea protezei metalice)
- * Endocardita infectioasa (necesita profilaxie permanenta)
- * Disfunctionalitatea protezei (trombi/vegetatii)
- * Mismatch-ul protezei (odata cu cresterea copilului)