



UNIUNEA EUROPEANĂ



GUVERNUL ROMÂNIEI



Fondul Social European
POSDRU 2007-2013



Instrumente Structurale
2007-2013



GUVERNUL ROMÂNIEI
MINISTERUL MUNCII, FAMILIEI,
PROTECȚIEI SOCIALE
ȘI PERSOANELOR VÂRSTNICE
OIRPOSDRU REGIUNEA CENTRU



UNIVERSITATEA DE MEDICINĂ ȘI
FARMACIE "CAROL DAVILA"
BUCUREȘTI

AD-COR Program inovativ de formare in domeniul cardiologiei pediatrice POSDRU/179/3.2/S/152012

Data: 16-11-2015

MODUL TEORETIC

Classificazione delle cardiopatie congenite

Imputernicit: Prof. Dr. Tammam Youssef

Activitate prestata de I.R.C.C.S. POLICLINICO SAN DONATO – MILANO, ITALIA in
baza contractului nr. 18/22144/29.07.2015



UNIUNEA EUROPEANĂ



GUVERNUL ROMÂNIEI



Fondul Social European
POSDRU 2007-2013



Instrumente Structurale
2007-2013



GUVERNUL ROMÂNIEI
MINISTERUL MUNCII, FAMILIEI,
PROTECȚIEI SOCIALE
ȘI PERSOANELOR VÂRSTNICE
OIROSDRU REGIUNEA CENTRU



UNIVERSITATEA DE MEDICINĂ ȘI
FARMACIE "CAROL DAVILA"
BUCUREȘTI

Acest material a fost documentat/ validat/ prezentat la sesiunile de formare în cadrul proiectului „AD-COR Program inovativ de formare în domeniul cardiologiei pediatrice” - POSDRU/179/3.2/S/152012, proiect cofinanțat din Fondul Social Operațional Sectorial Dezvoltarea Resurselor Umane 2007-2013.

Beneficiar: Universitatea de Medicină și Farmacie „Carol Davila” București

Conținutul acestui material nu reprezintă în mod obligatoriu poziția oficială a Uniunii Europene sau a Guvernului României

Università di Pisa
Scuola di Specializzazione in Cardiologia

Seminario

Classificazione delle cardiopatie congenite

Sandra Giusti

Fondazione Gabriele Monasterio
Cardiologia Pediatrica
Ospedale del Cuore G.Pasquinucci, Massa

Peacock TB

On malformation of the human heart

London: John Churchill 1858

Abbot M.E.

Atlas of congenital cardiac disease

New York: American Heart Association, 1936

Shinebourne E.A., MaCartney F.J., Anderson R.H.

**Sequential chamber localization: the logical approach to
the diagnosis in congenital heart disease**

Br Heart J, 1976; 38: 327-340

Sequential segmental analysis



ATRIA

➤ **SITUS AND VENOUS CONNECTION**

VENTRICLES

➤ **A-V CONNECTION**

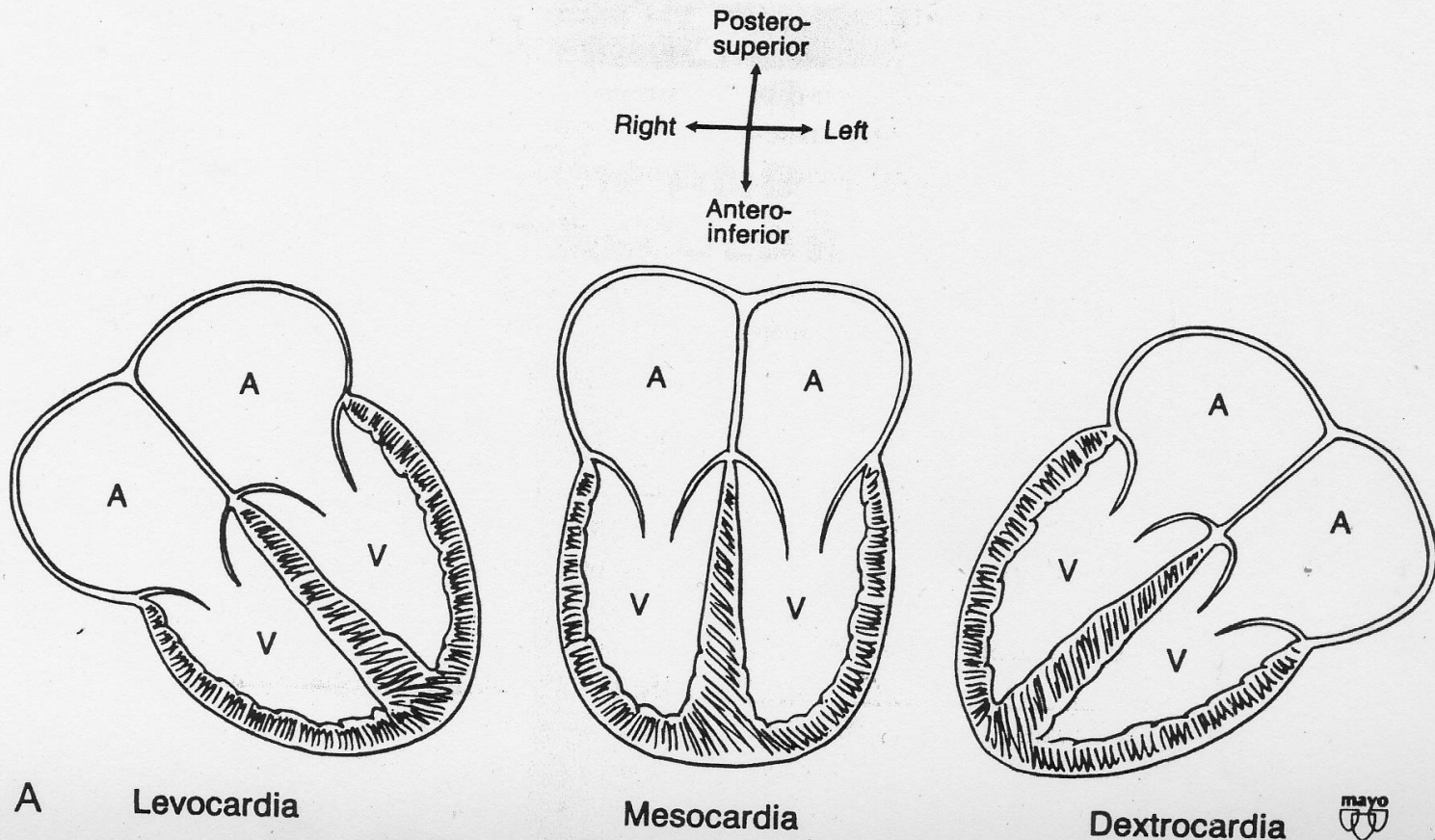
GREAT ARTERIES

➤ **V-A CONNECTION**

Cardiac position

- **Left-sided**
- **Right-sided**
- **Midline**
- **Ectopia cordis (cervical, thoracic, abdominal)**

Orientation in the chest



Visceral sidedness (situs)

- Cardiovascular
- Respiratory
- Digestive

situs solitus

situs inversus

situs ambiguus (isomeric or indeterminate)

Isomerism

➤ Right isomerism = bilateral right sidedness

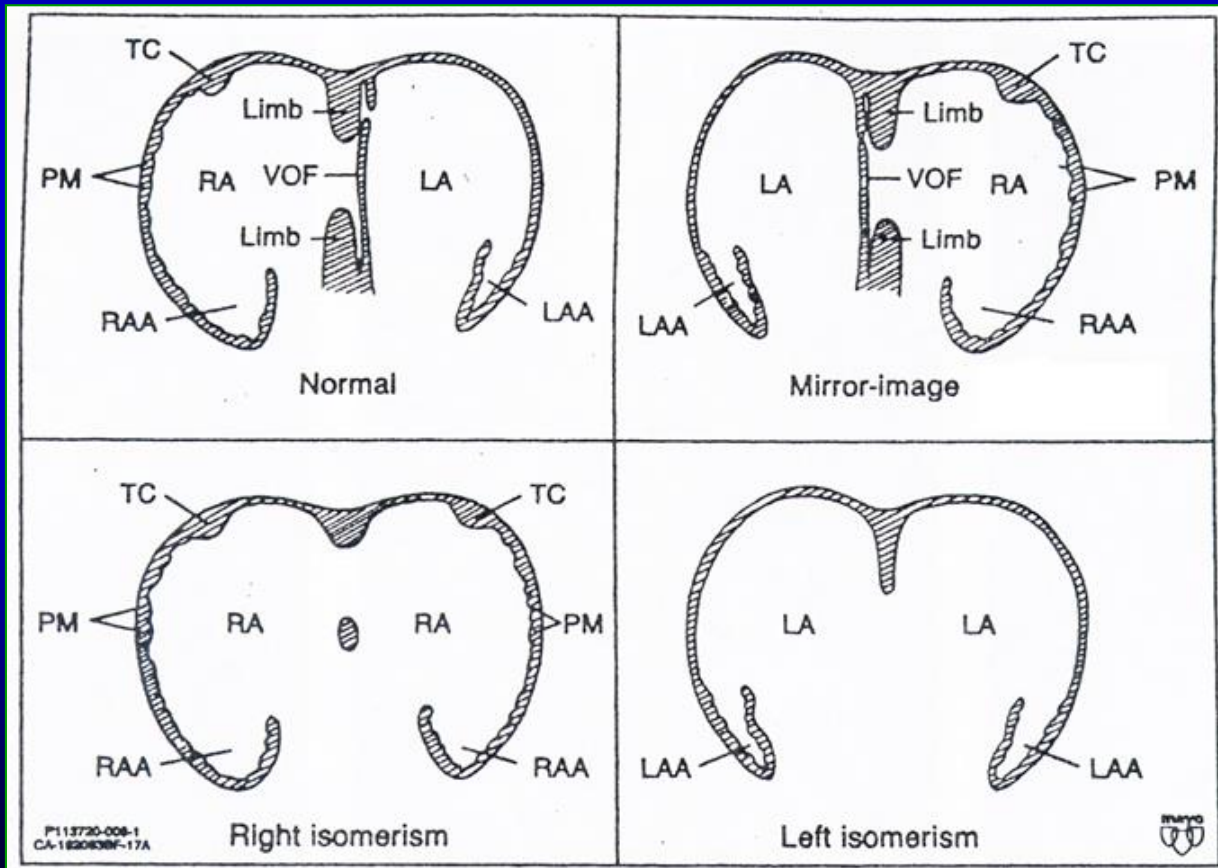
asplenia

➤ Left isomerism = bilateral left sidedness

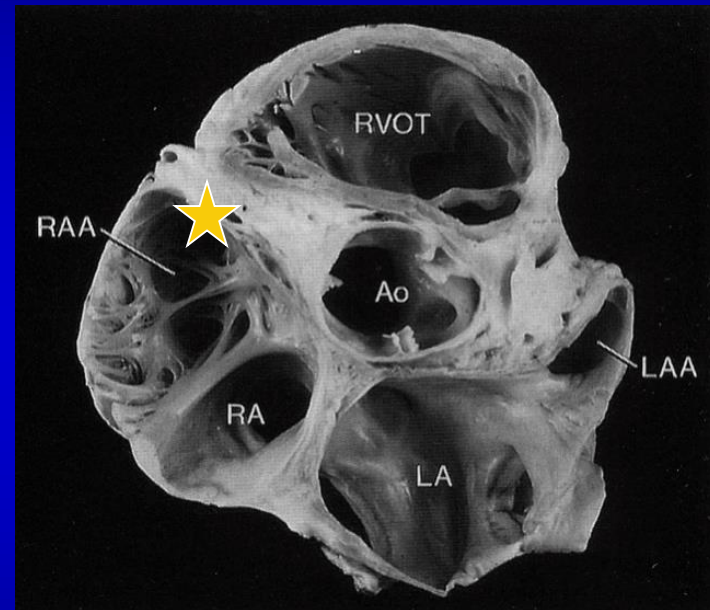
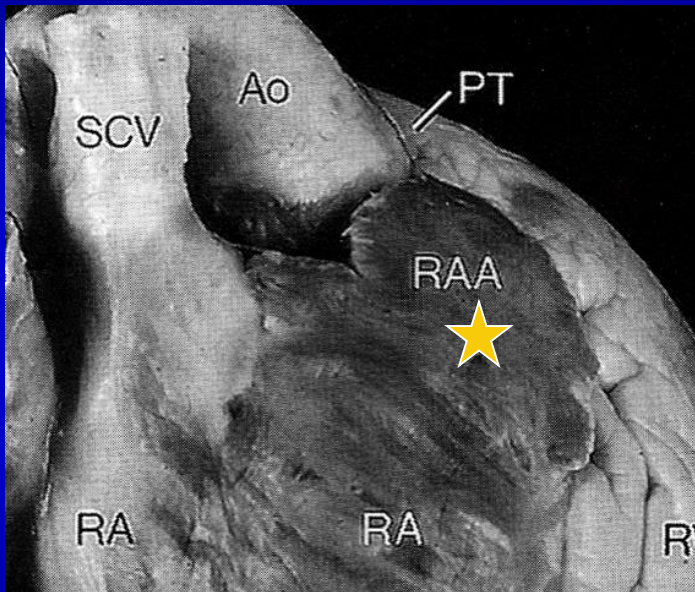
polysplenia

Cardiac sidedness

Position of the morphologic right atrium



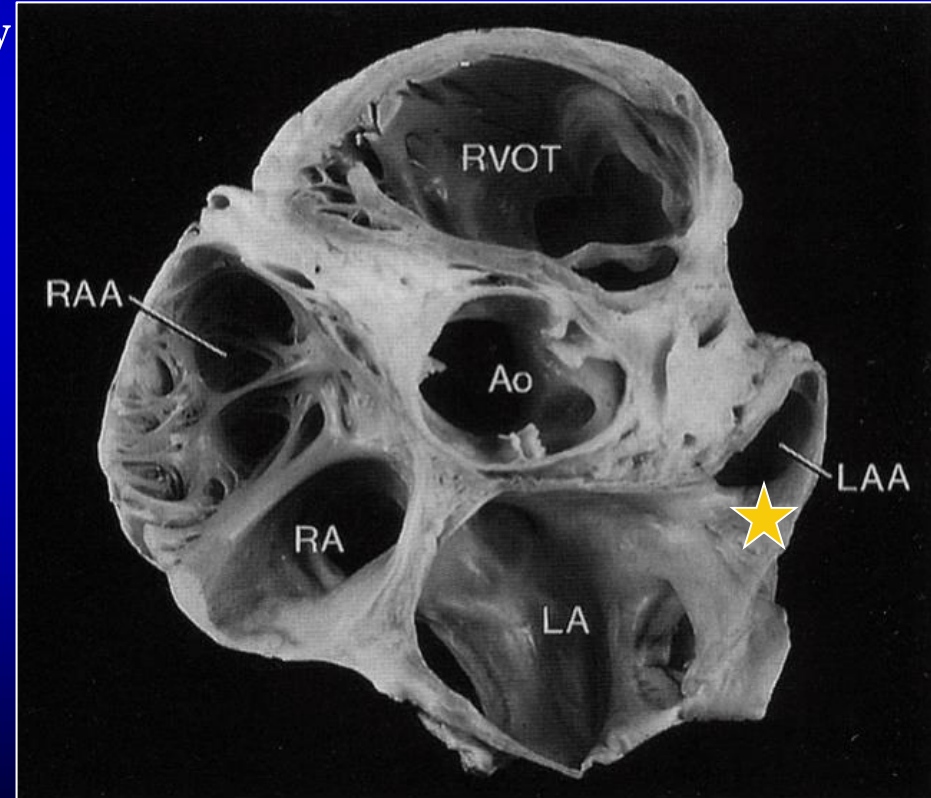
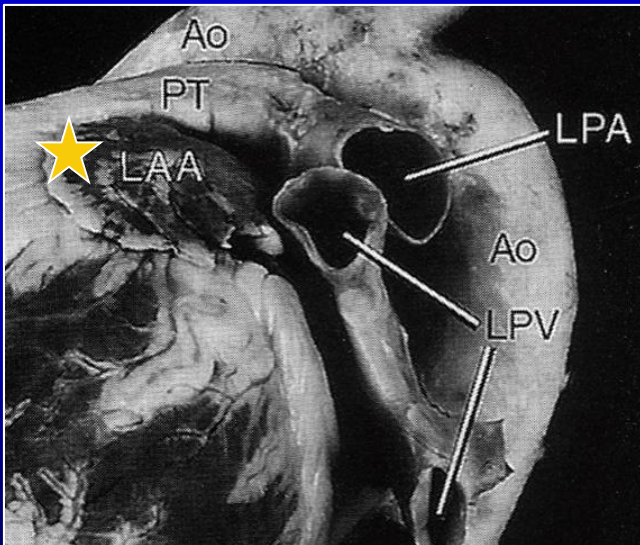
Morphology of the right atrium



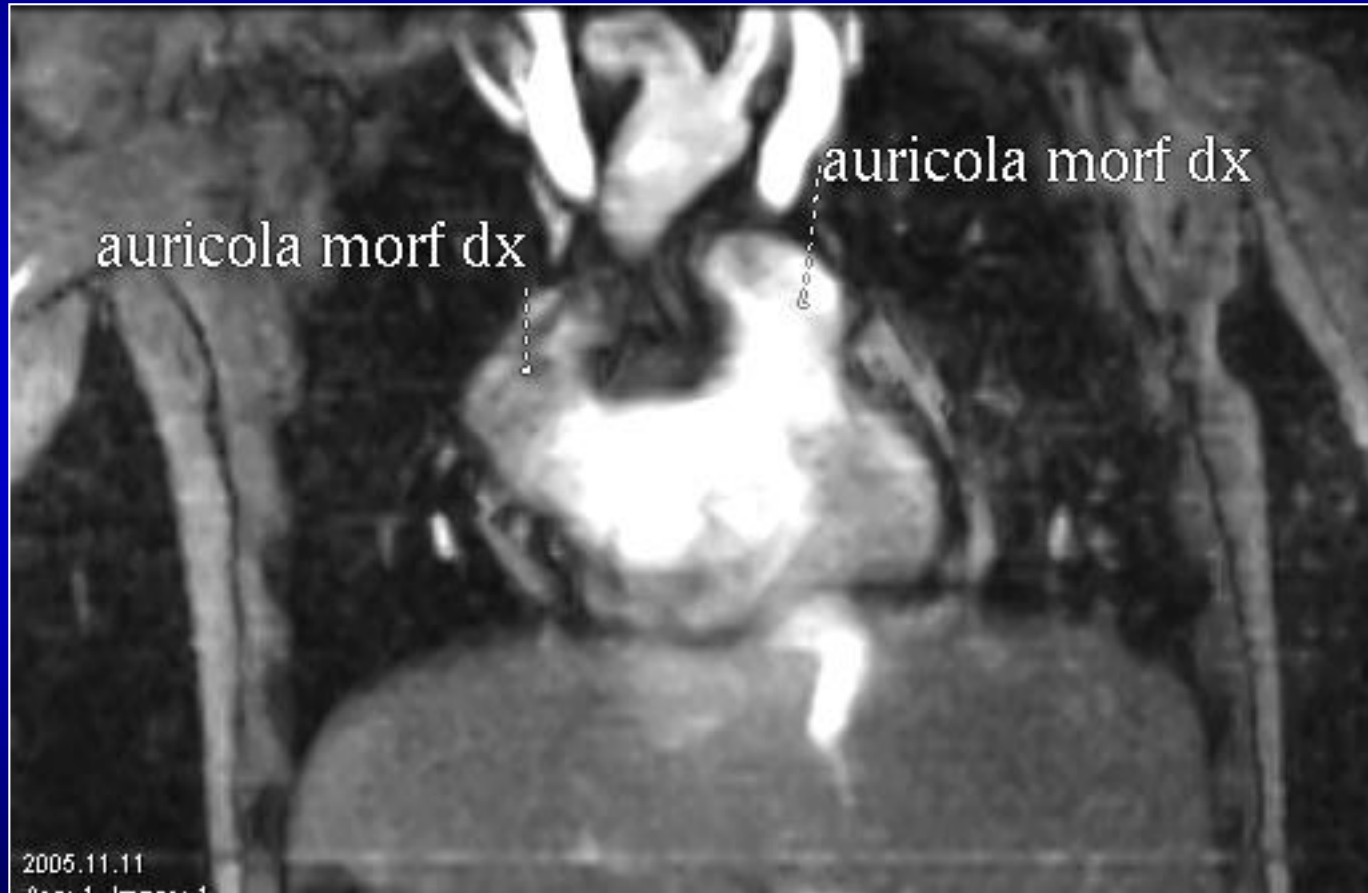
- **triangular shape**
- **large communication with atrial cavity**

Morphology of the left atrium

finger-like
narrow communication with atrial cavity

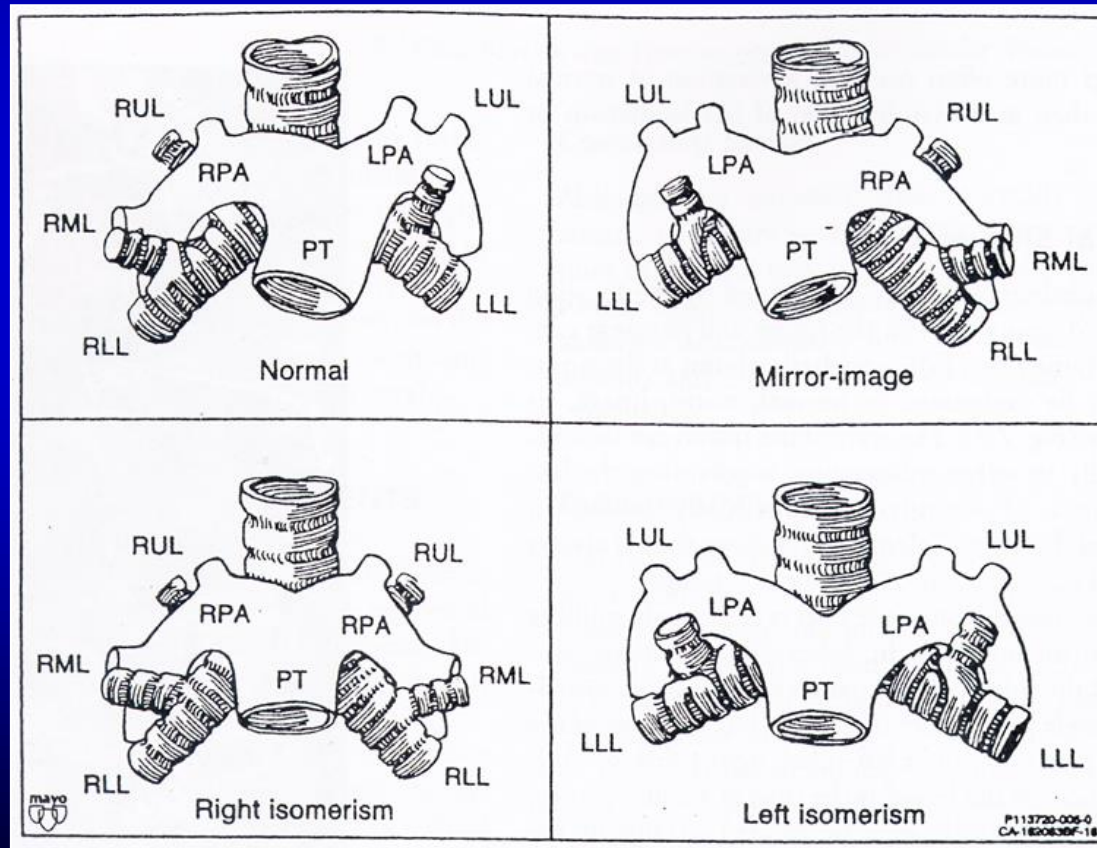


Isomerism

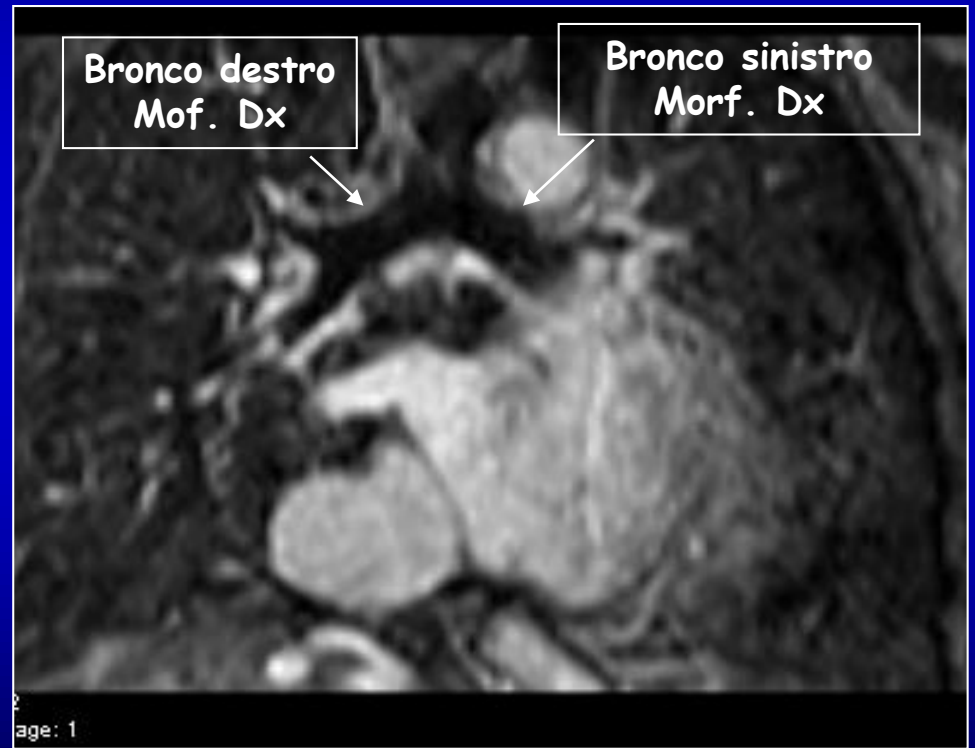
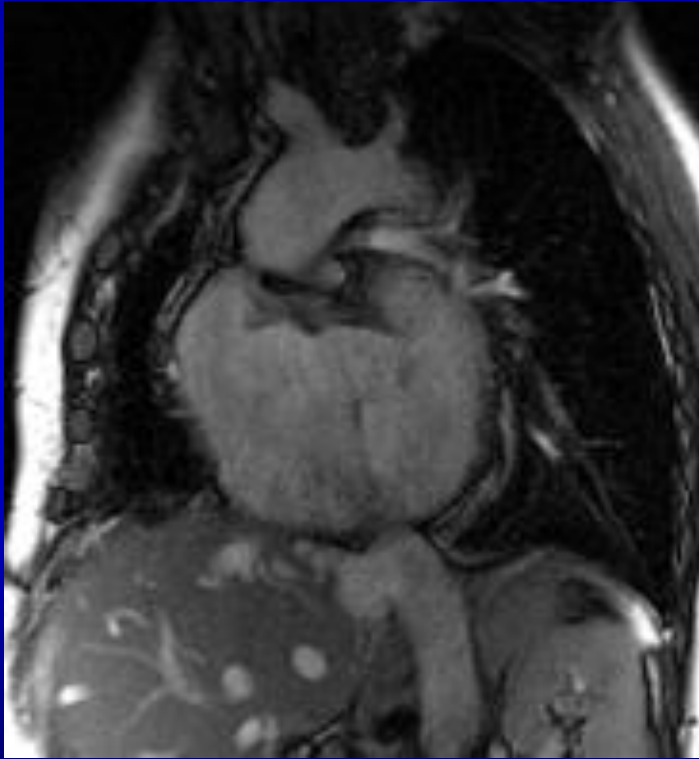
Pulmonary sidedness

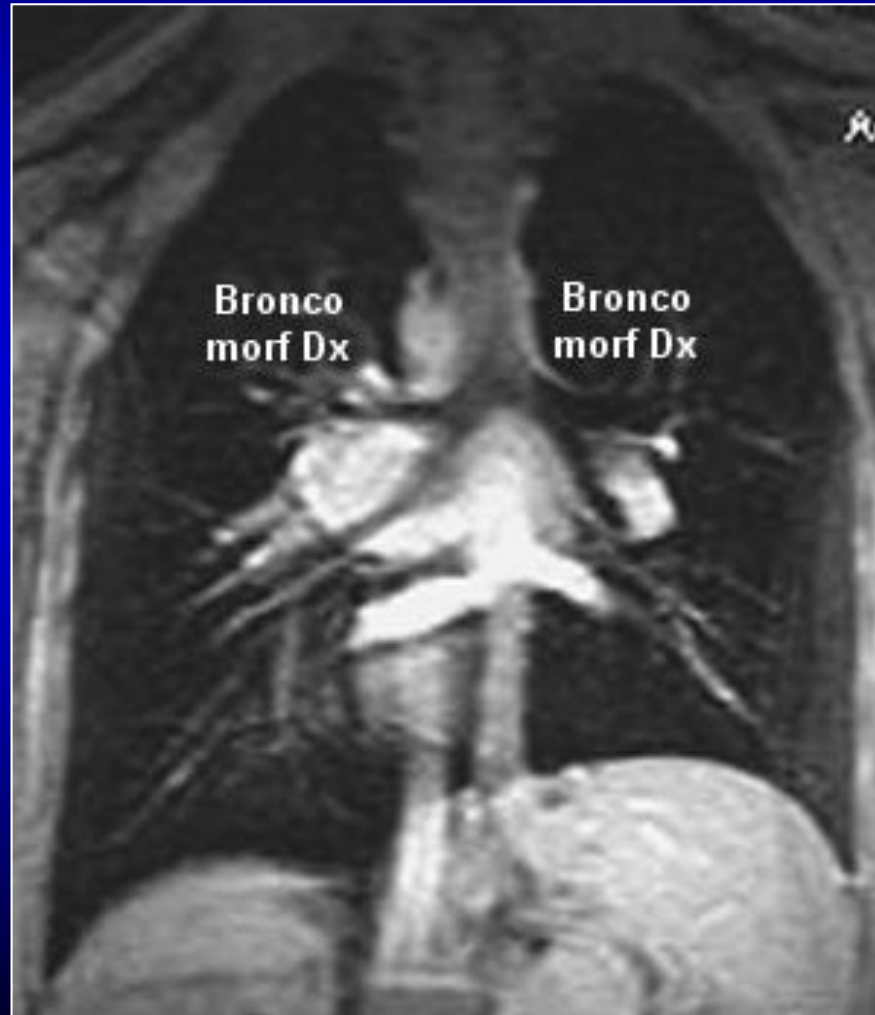
Positions of the morphologic right and left lungs



Isomerism

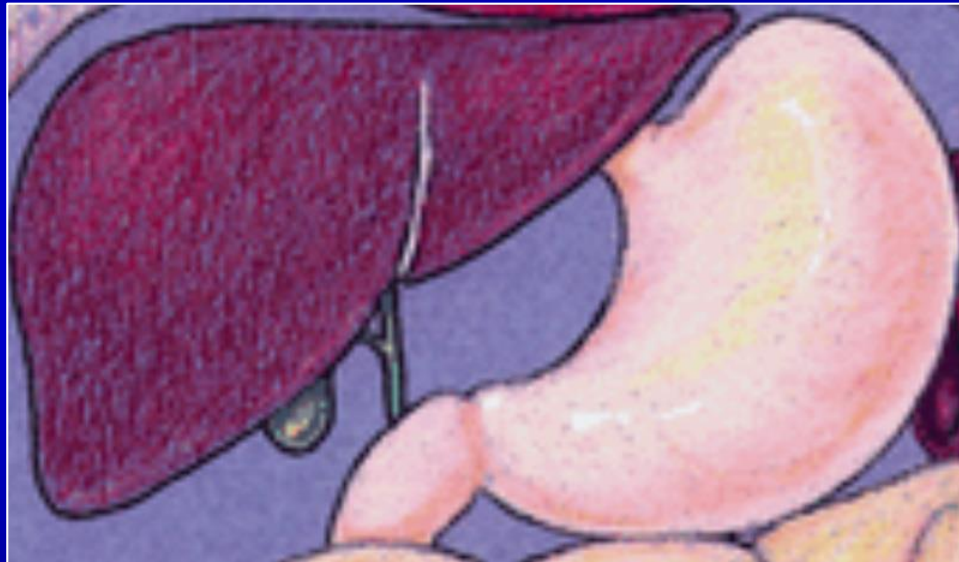


Isomerism



Abdominal sidedness

location of the liver and the stomach



Spleen (if present) and pancreas generally on the same side of the vertebral column as the stomach

Situs assessment

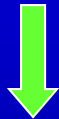Atriovisceral situs



DETERMINED



SOLITUS



INVERSUS

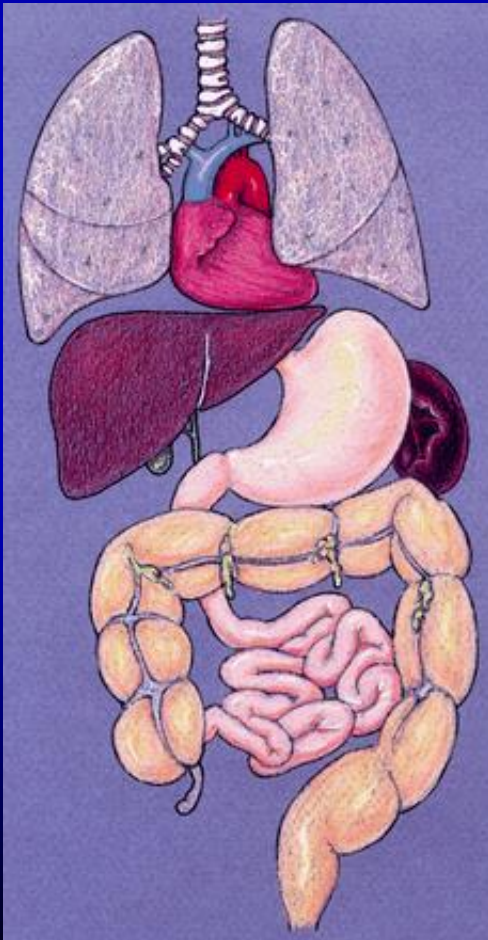
(mirror image)



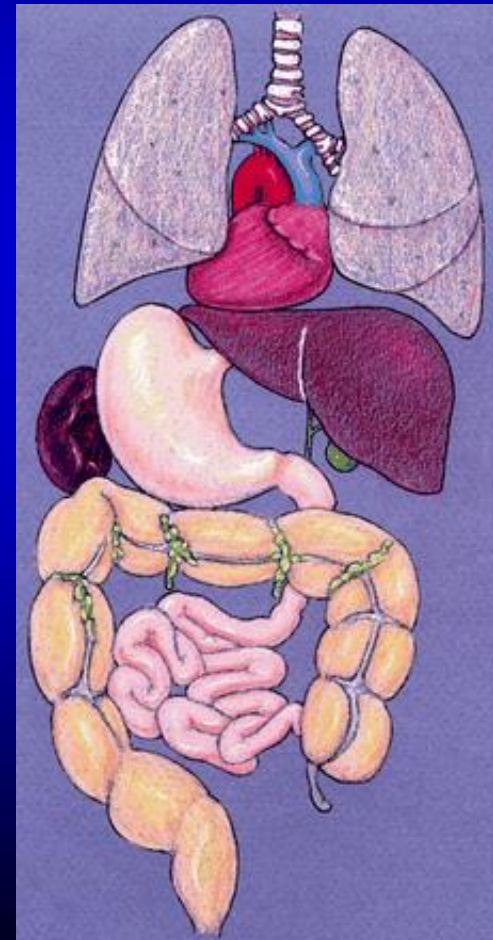
UNDETERMINED
(HETEROTAXY / SITUS
AMBIGUUS)

Determined Atriovisceral Situs

SITUS SOLITUS



SITUS INVERSUS

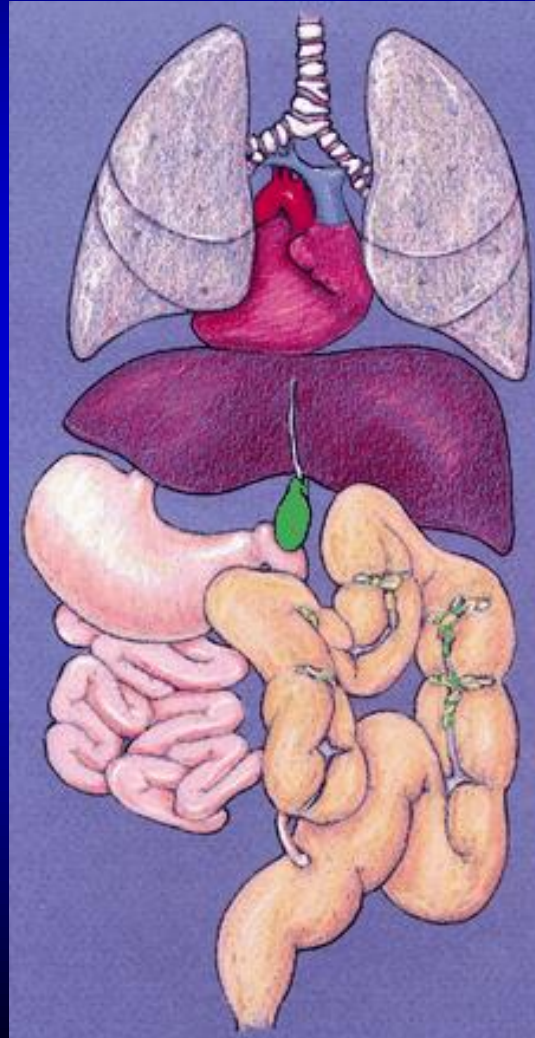


Right isomerism

2 R bronchi

2 R atria

Midline liver



Absent spleen



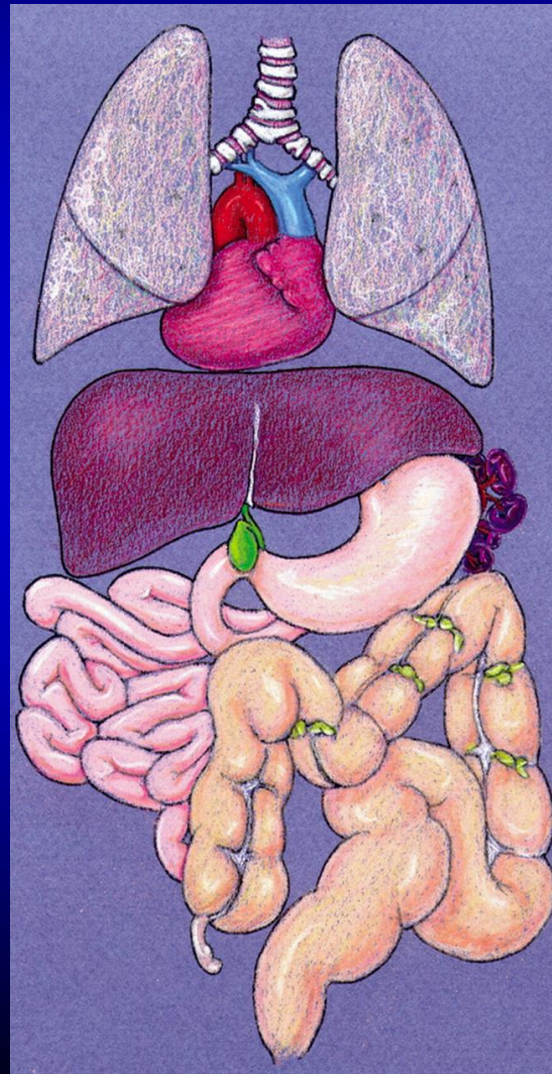
*asplenia
syndrome*

Left isomerism

2 L bronchi

2 L atria

Sidedness of
abdominal viscera
indeterminate,
mirror-image or
normal



Supranumerary spleens

→ *polysplenia
syndrome*

Venous connections

**SYSTEMIC VENOUS
connection**

**Superior vena cava
(SVC)**



MORPH. R ATRIUM



**Inferior vena cava
(IVC)**

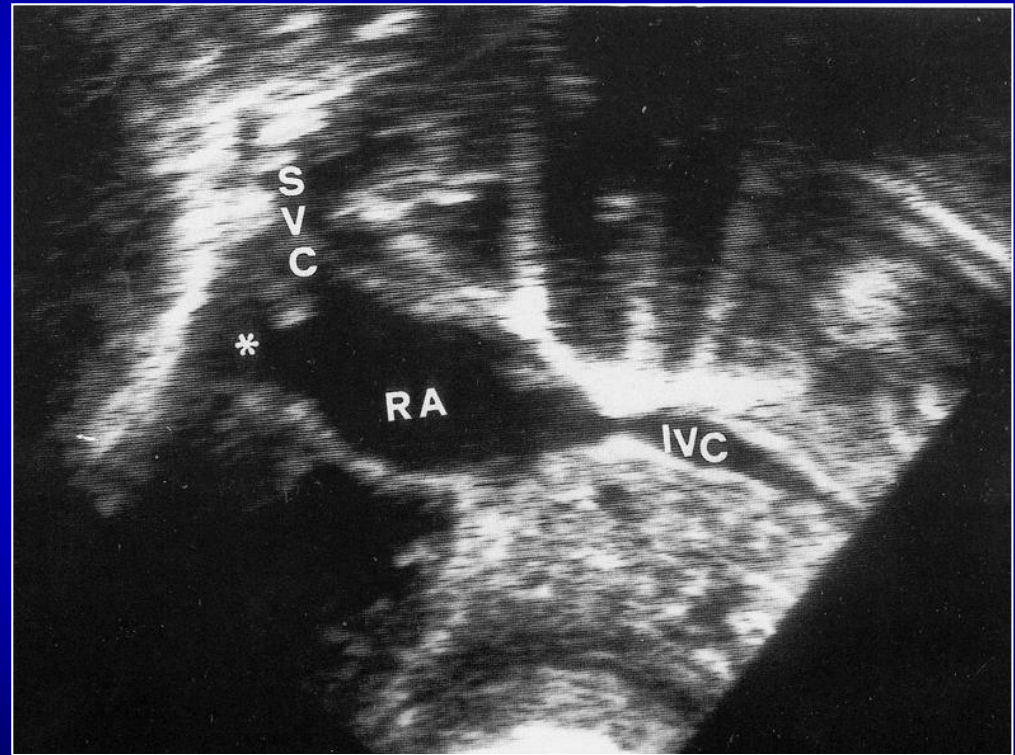
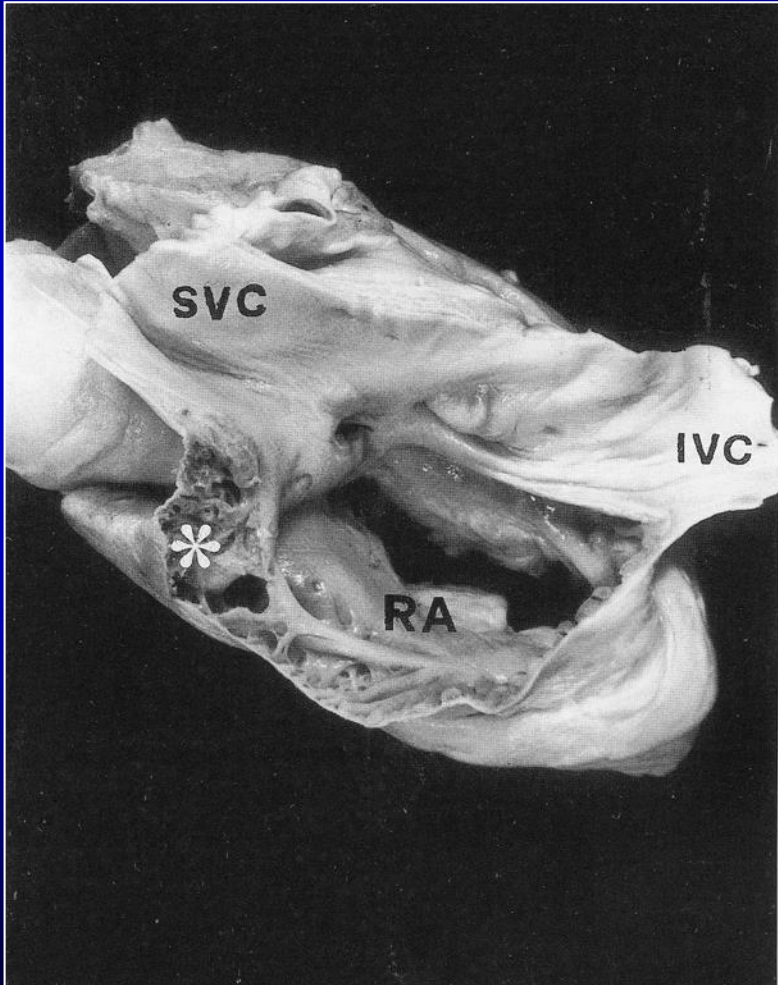
**PULMONARY VENOUS
connection**

4 pulmonary veins

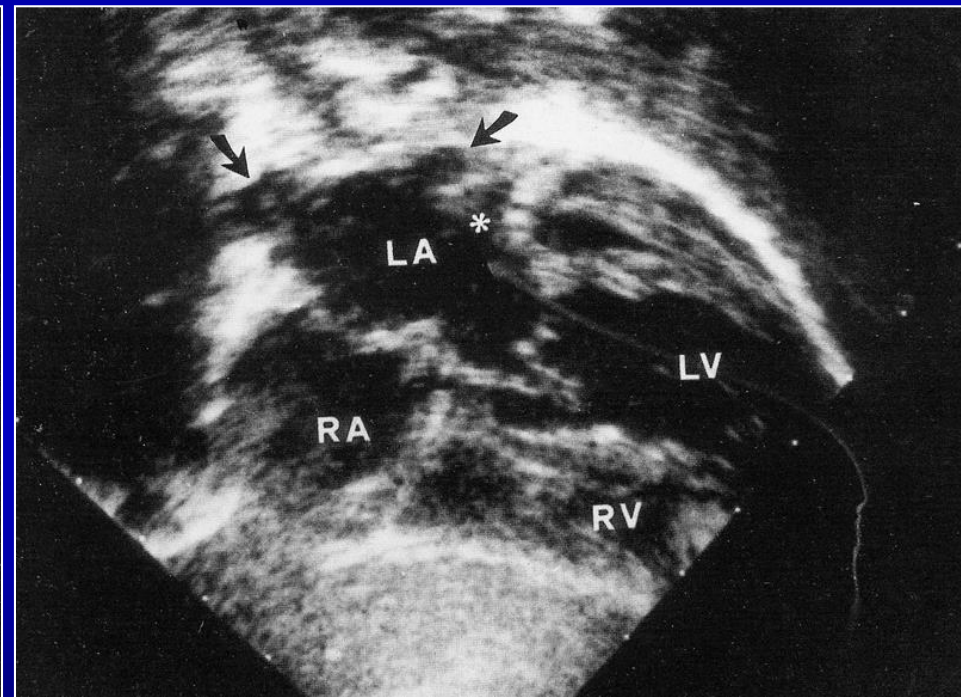
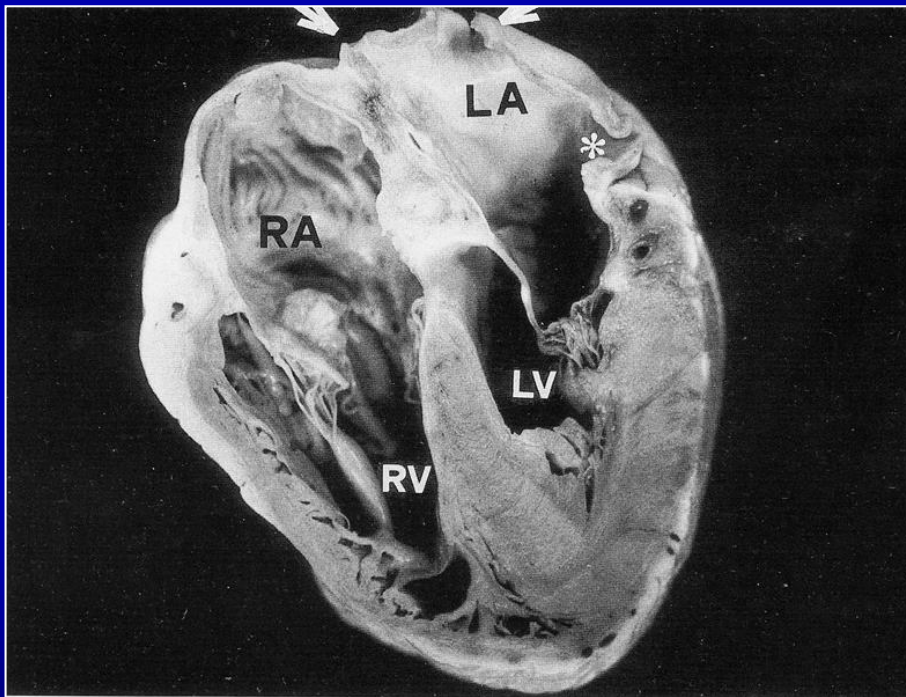


MORPH. L ATRIUM

Venous connections

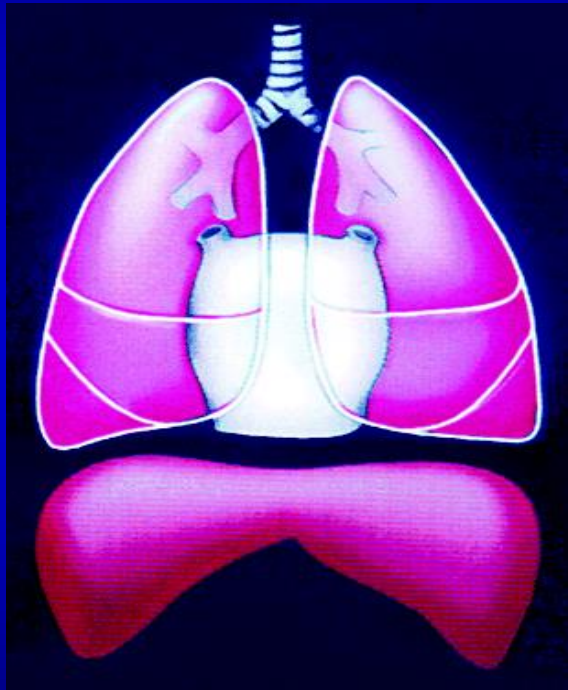

Venous connections



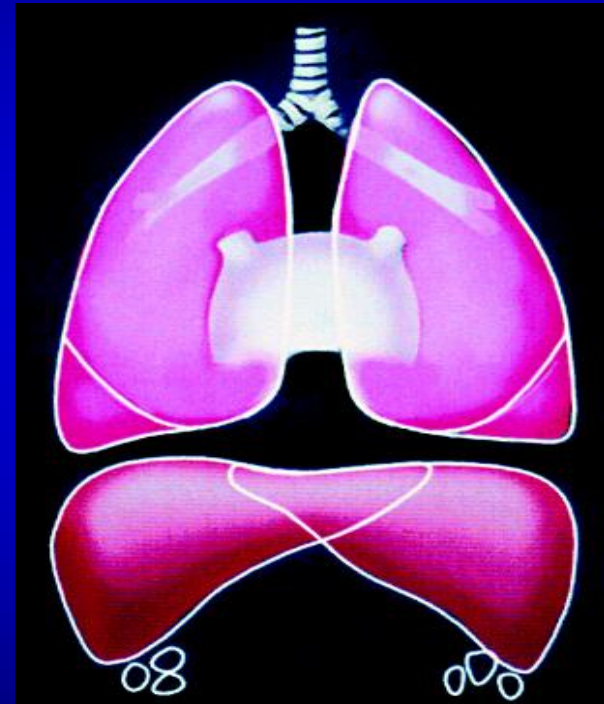
Venous connections

RIGHT ISOMERISM



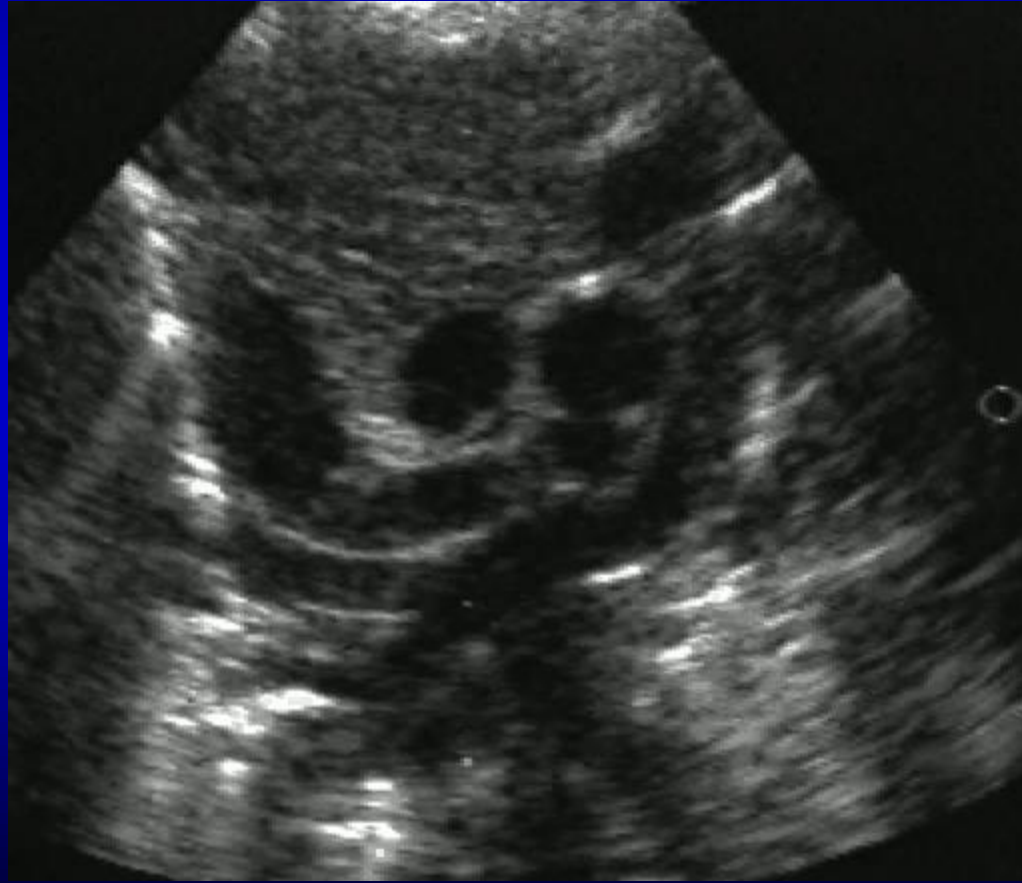
- IVC and hepatic veins drain separately
- 2 superior caval veins
- TAPVD

LEFT ISOMERISM

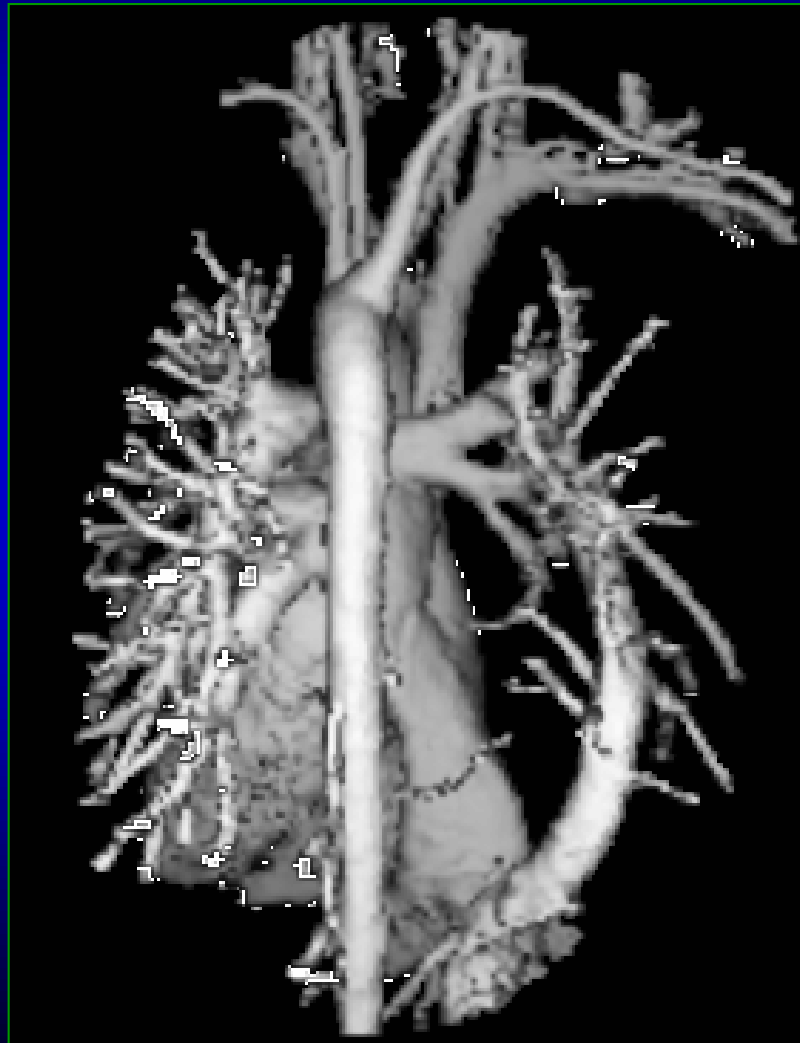

- Interruption of suprahepatic tract of IVC and azygos continuation
- Pulmonary venous drainage into both atria

Anomalous venous connection



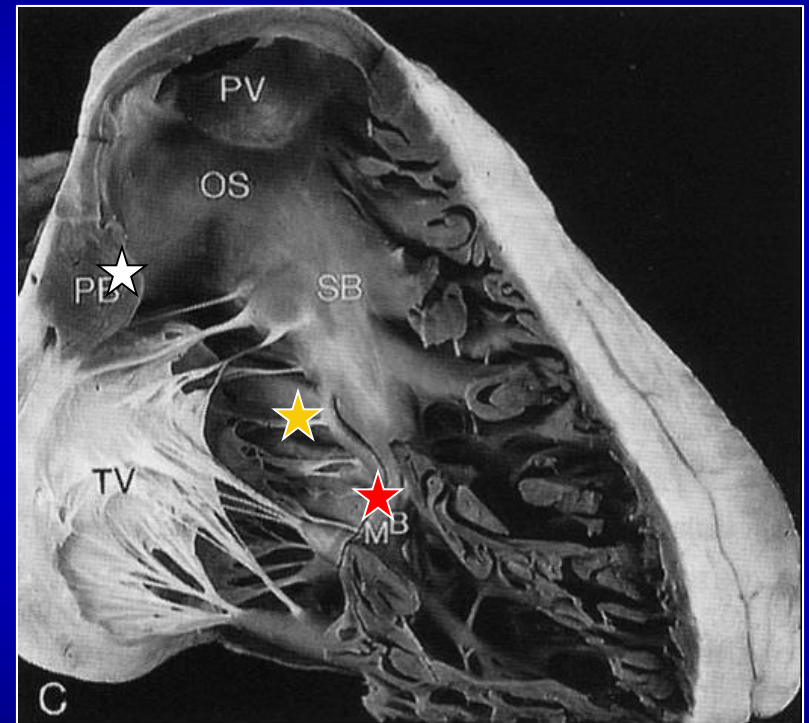
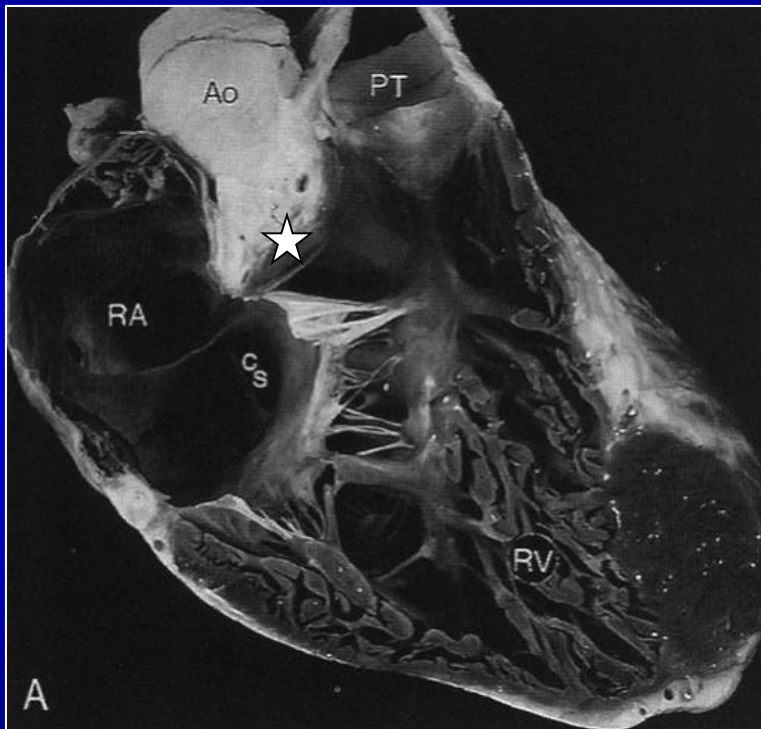
Anomalous venous connection



Atrioventricular connections

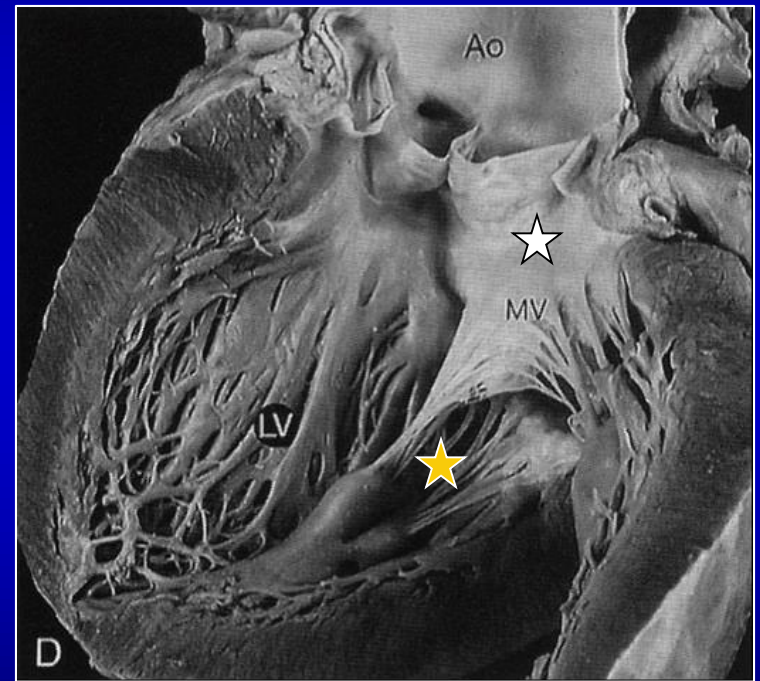
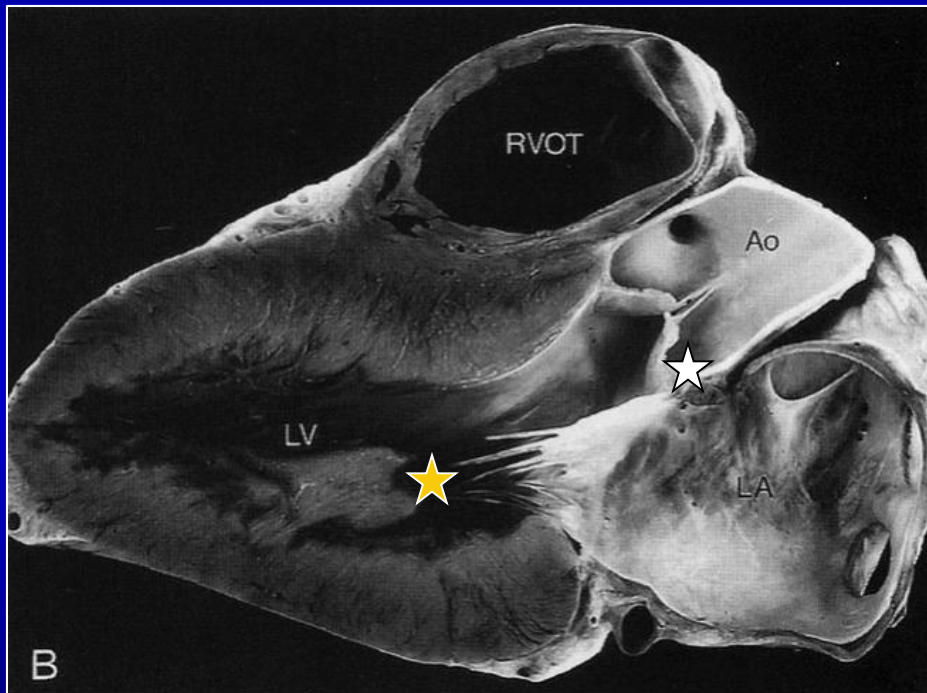
- Biventricular :
 - Concordant
 - Discordant
 - Ambiguous
- Univentricular:
 - Double inlet
 - Single inlet
 - Common inlet

Morphology of the right ventricle



heavy trabeculations
moderator band
ventriculo-infundibular fold
morphology of tricuspid valve

Morphology of the left ventricle



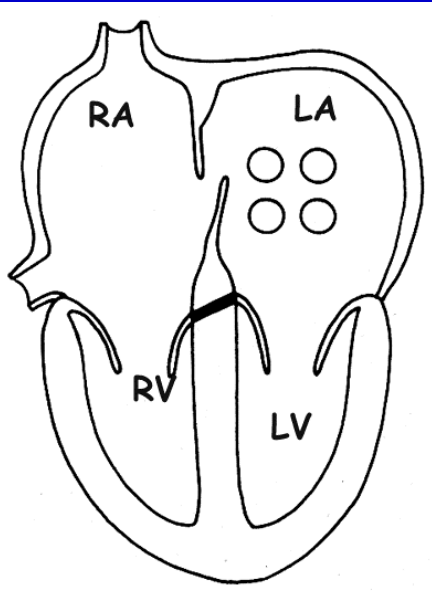
smooth endocardial surface, fine apical trabeculations
mitro-aortic fibrous continuity
morphology of mitral valve

Atrioventricular Connection

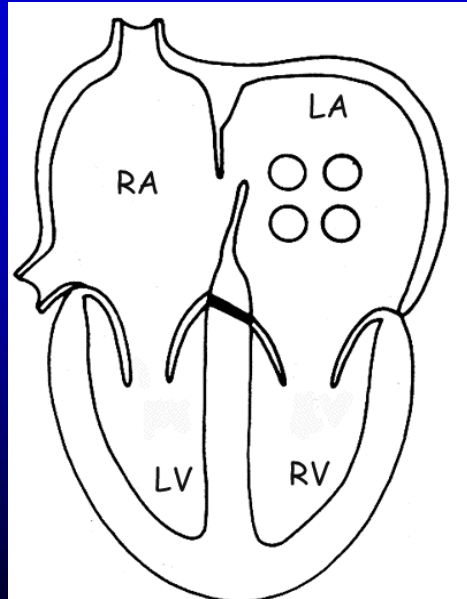
Biventricular Connection

atria are connected with two distinct ventricles

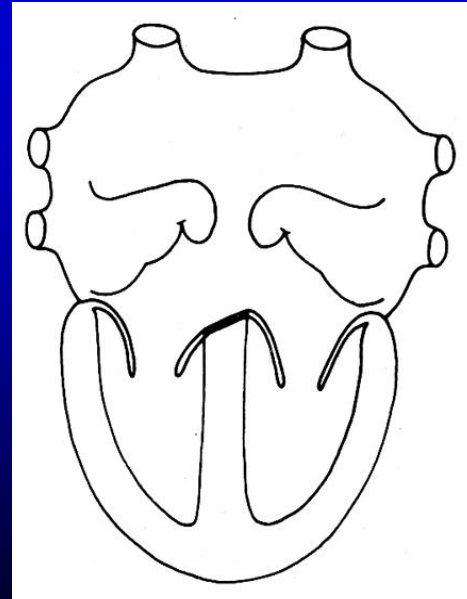
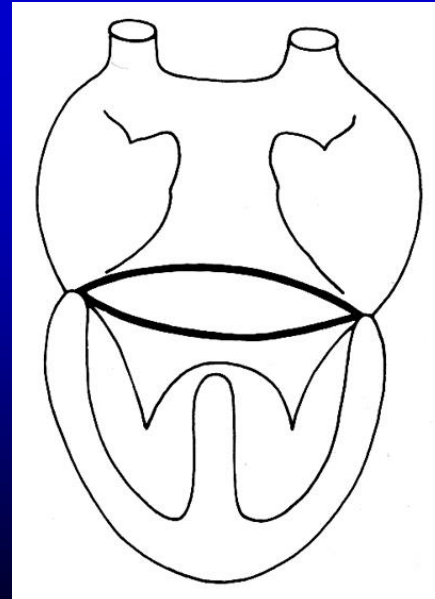
concordant



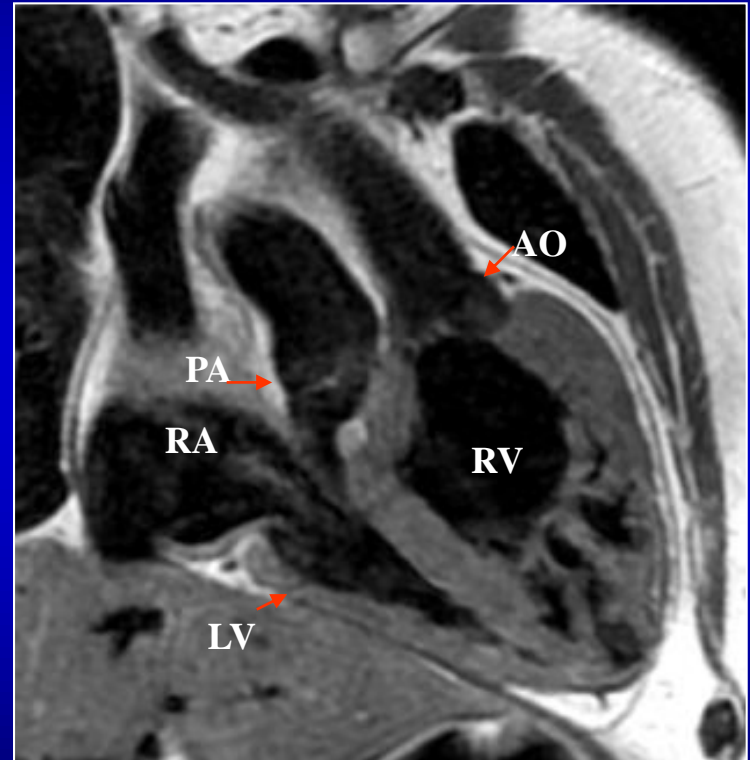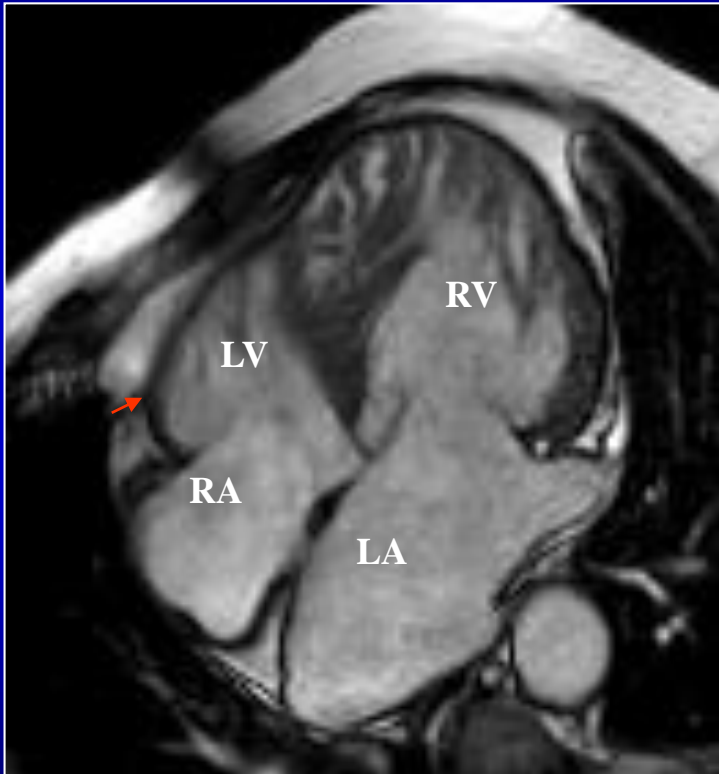
discordant



ambiguous



cTGA

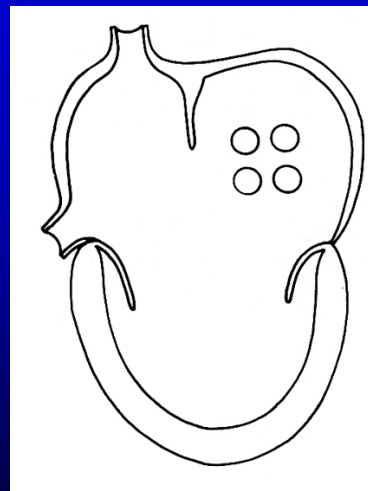
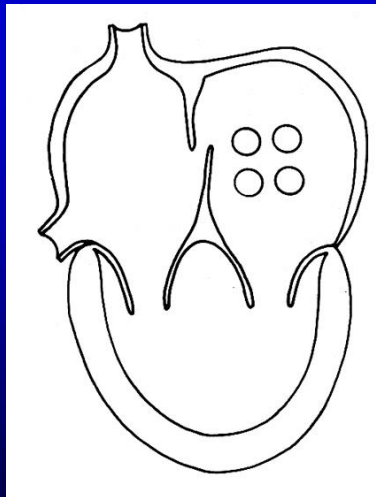


Atrioventricular Connection

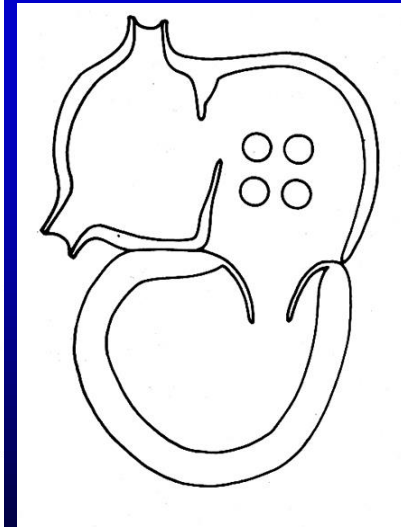
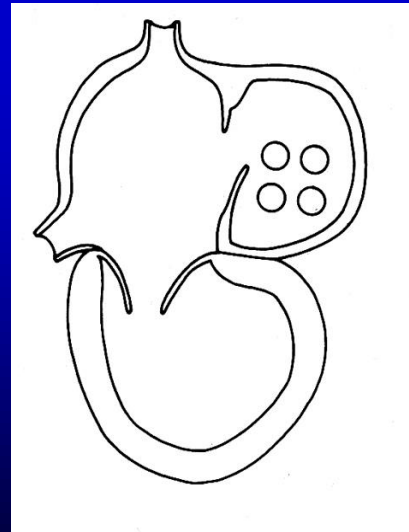
Univentricular Connection

atria are connected with a single ventricle

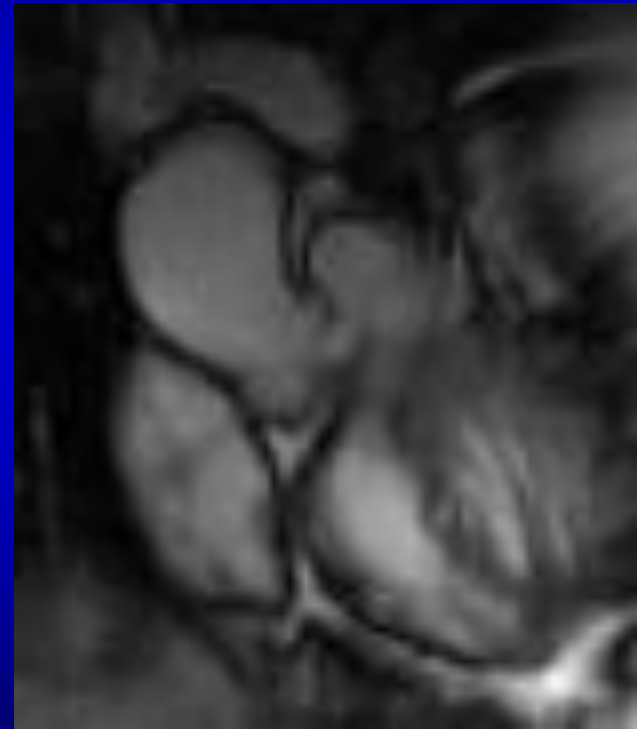
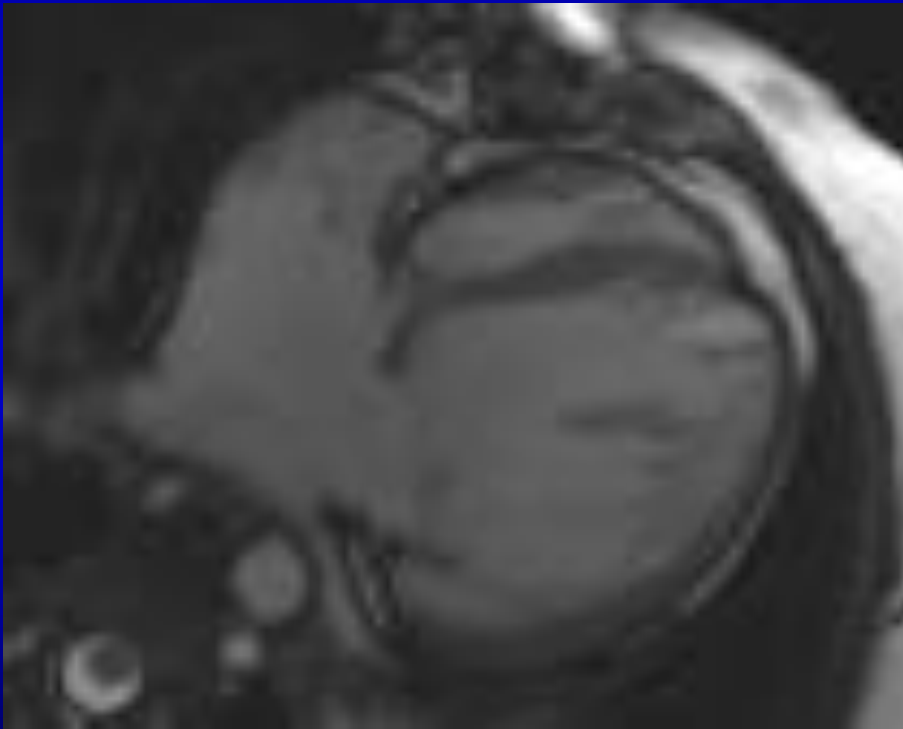
Double inlet Common inlet



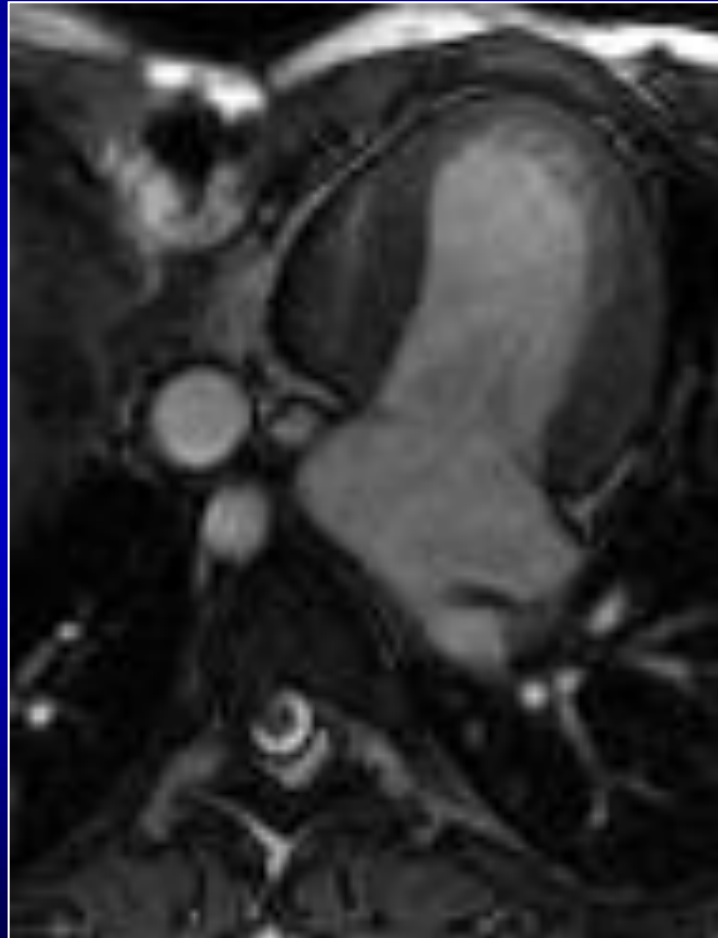
Single inlet



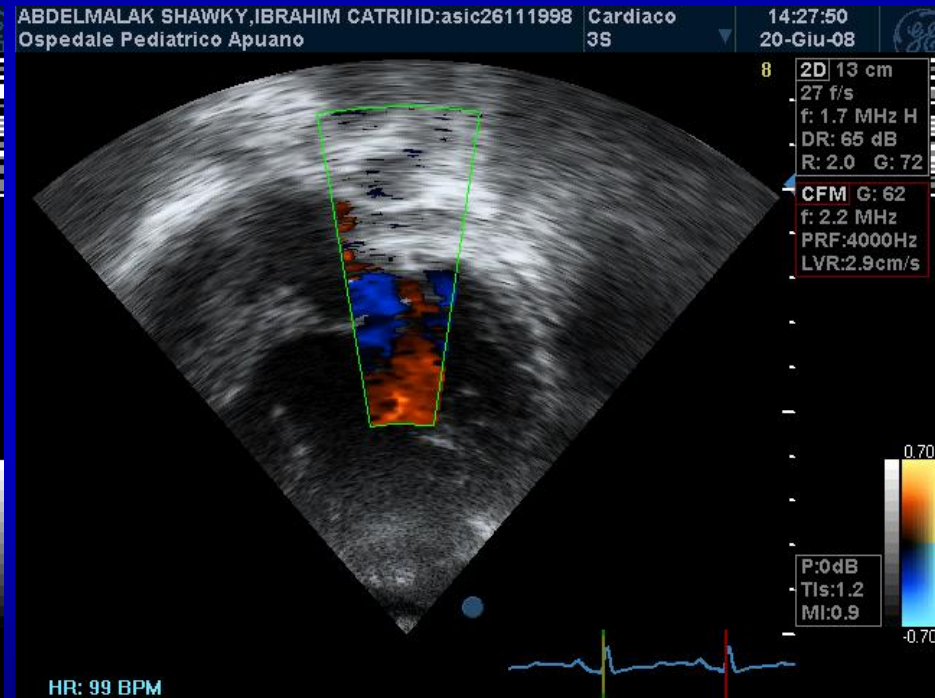
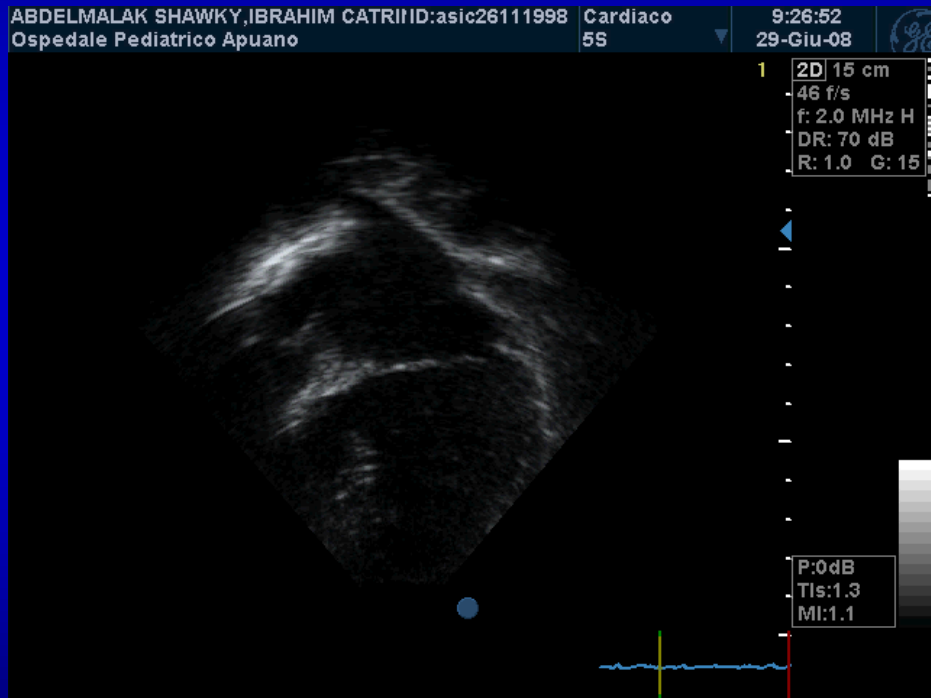
Tricuspid atresia



Tricuspid atresia



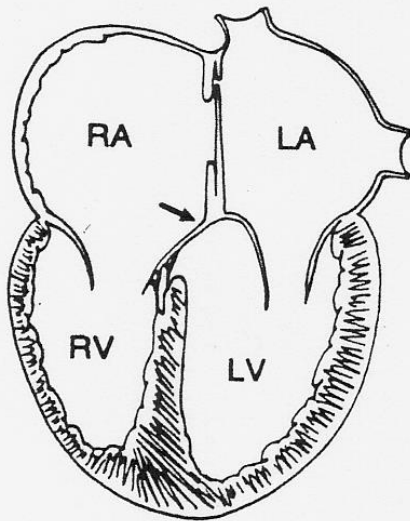
Tricuspid atresia



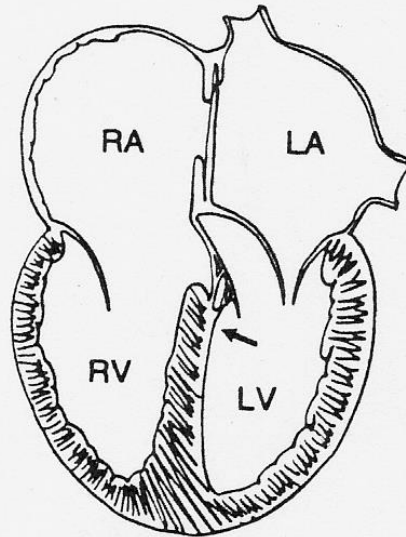
Atrioventricular Connection

Straddling/Overriding

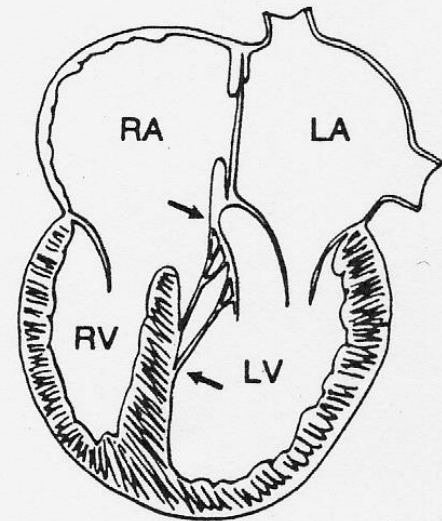
OVERRIDING



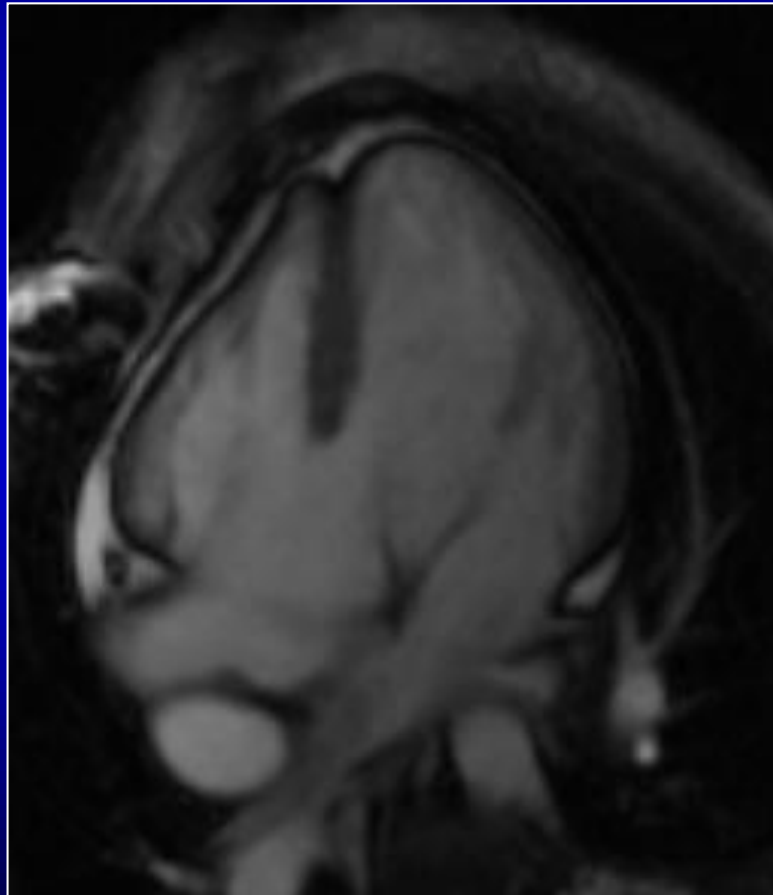
STRADDLING



STRADDLING WITH
OVERRIDING



Straddling atrioventricular valve

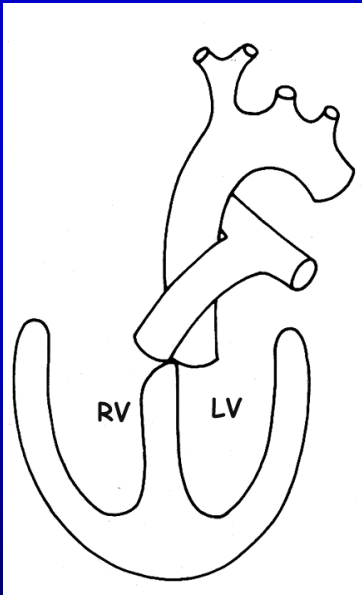


Atrioventricular connections

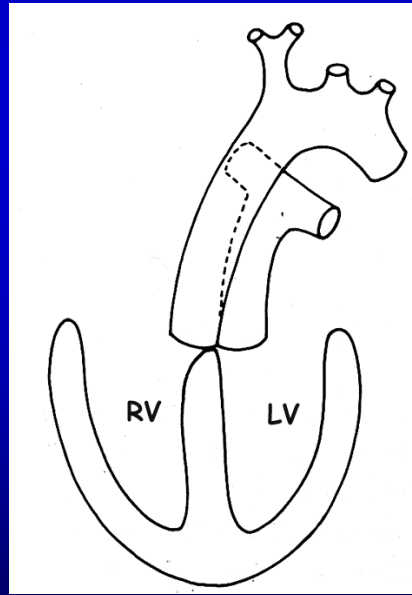
- **Concordance**
- **Discordance**
- **Double outlet**
- **Single outlet**
- **Common outlet**

Atrioventricular connections

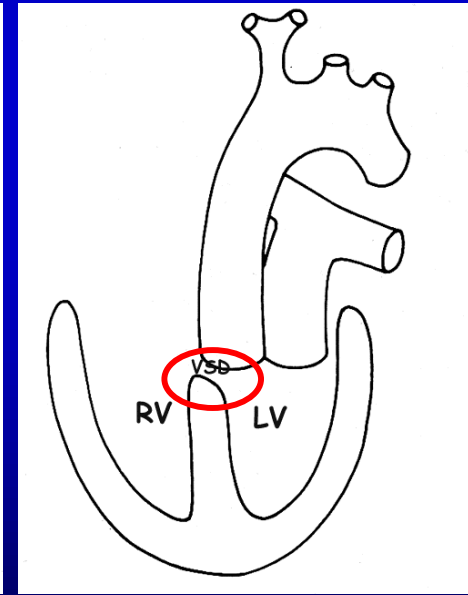
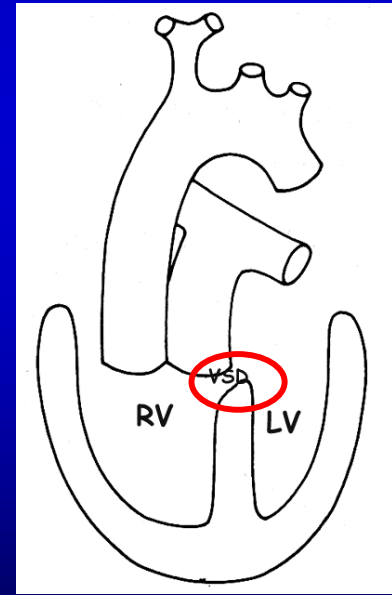
CONCORDANT



DISCORDANT



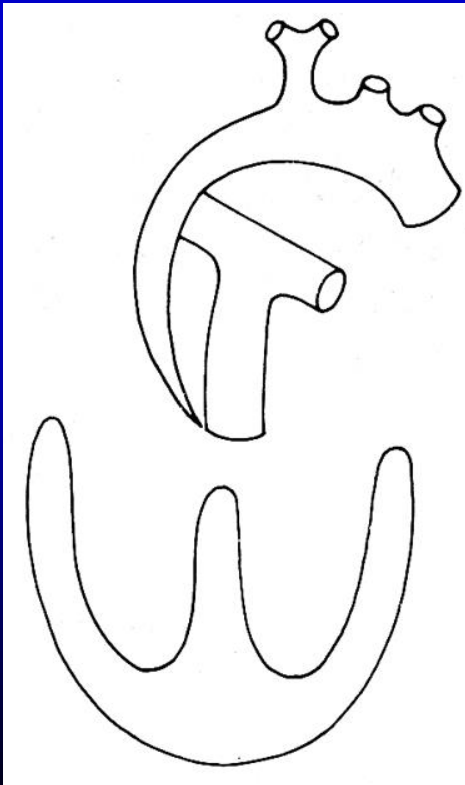
DOUBLE OUTLET



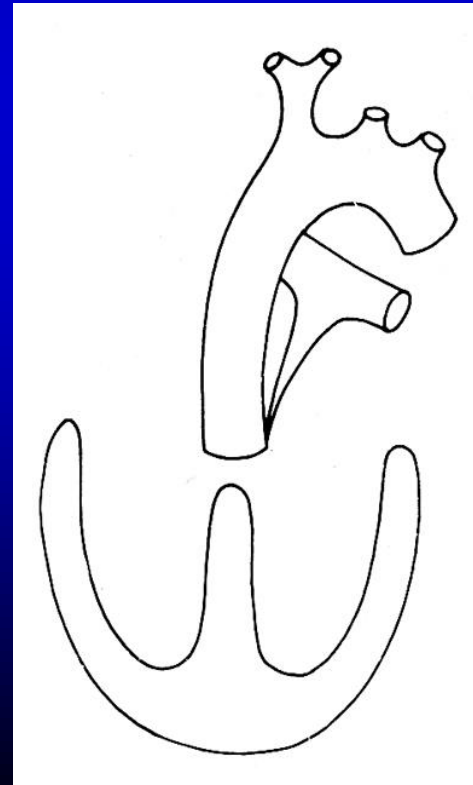
Atrioventricular connections

Single Outlet

Ao Atresia

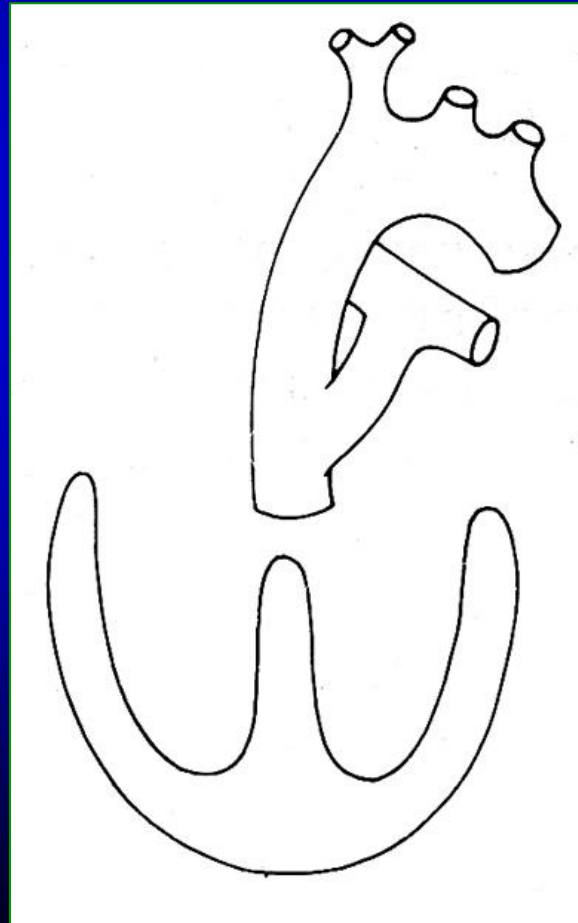


Pul. Atresia

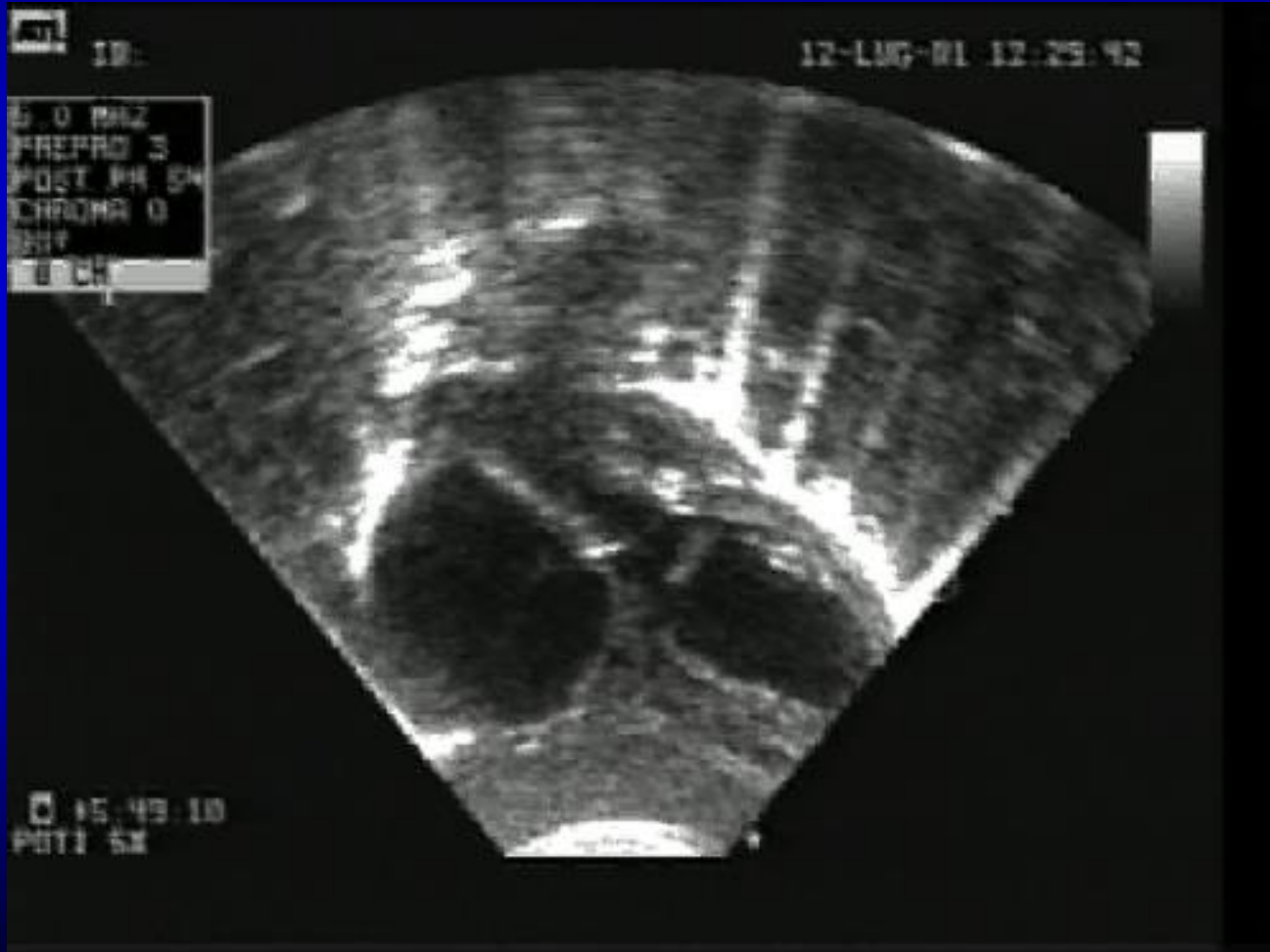


Atrioventricular connections

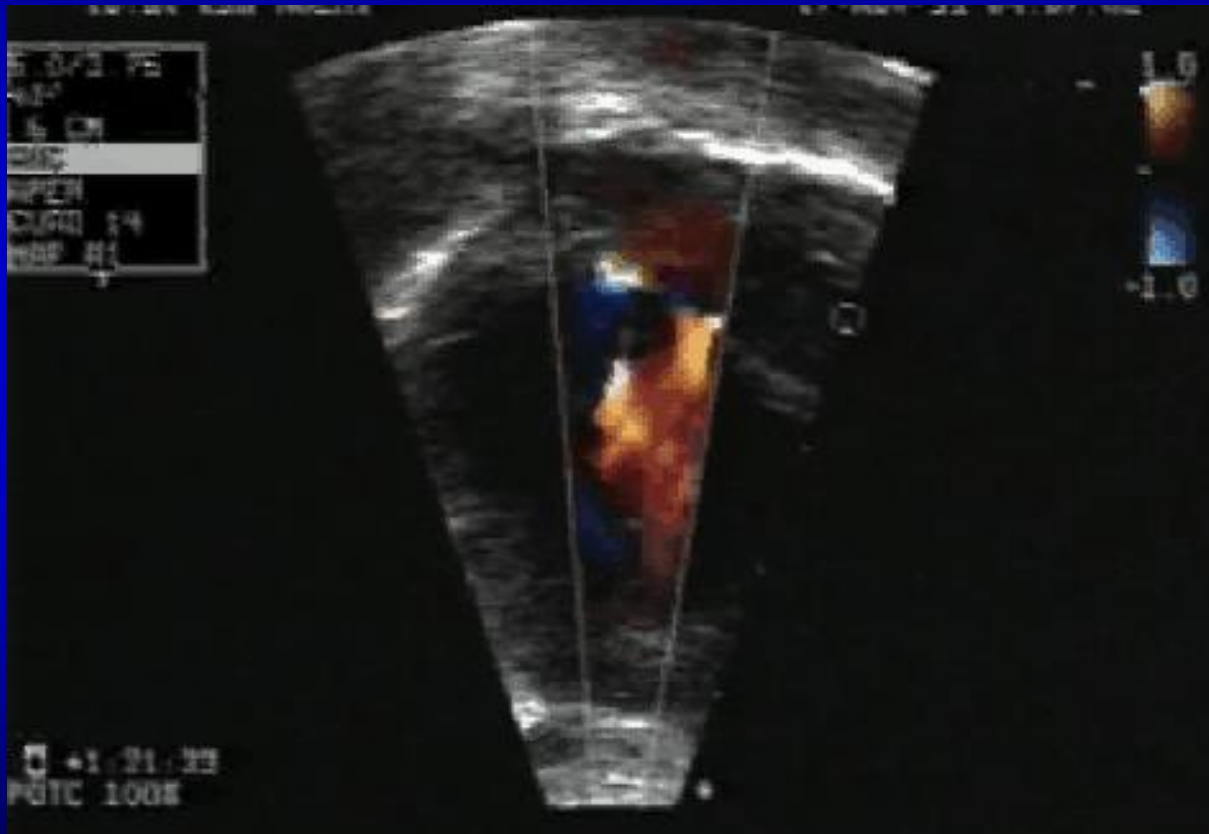
Common outlet



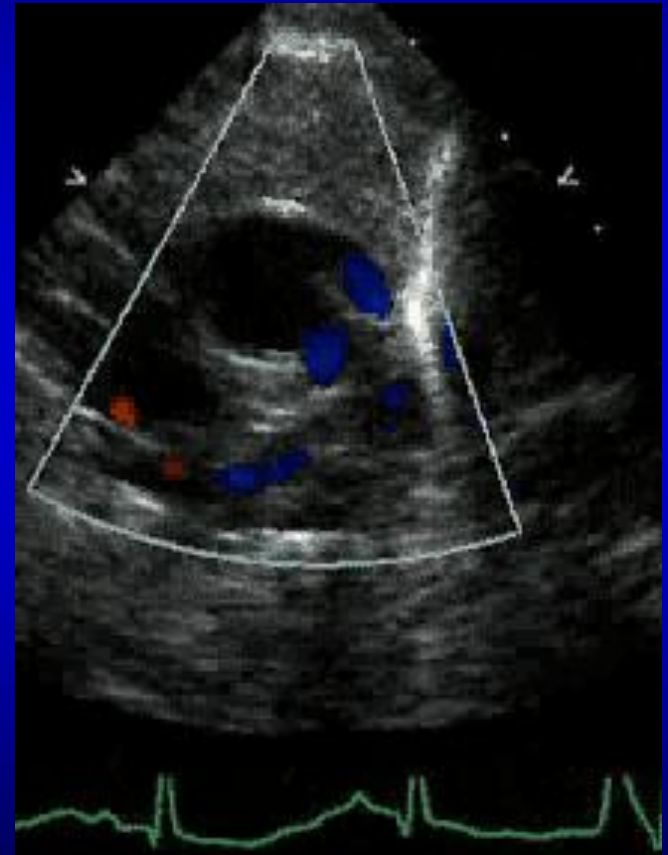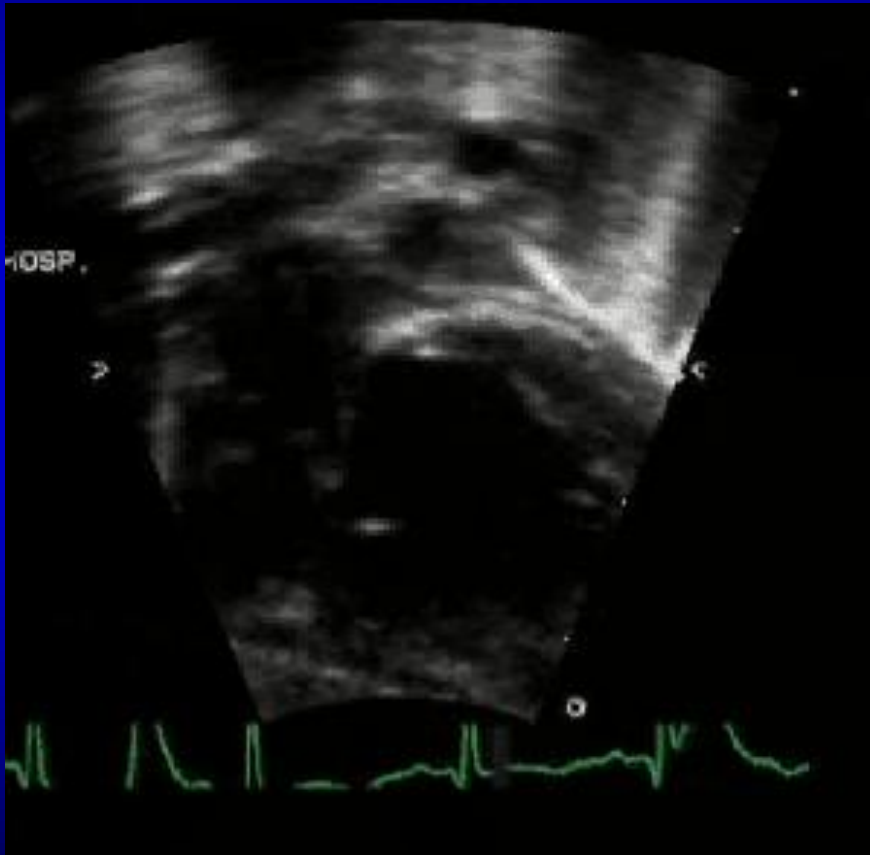
Transposition of the Great Arteries



Aortic atresia



Truncus



Diagnostic tools

➤ Chest X-Ray

- bronchial morphology
- position of heart and cardiac apex
- position of liver and stomach

➤ Abdominal Echo

- position of liver and stomach
- presence (and number) of spleen(s)
- position of aorta and vena cava

➤ Echocardiography

➤ Cardiovascular MRI

➤ Cardiac Catheterization

Università di Pisa
Scuola di Specializzazione in Cardiologia
Direttore Prof. Alberto Balbarini

Seminario

Classificazione delle cardiopatie congenite

Sandra Giusti

Fondazione Gabriele Monasterio
Cardiologia Pediatrica
Ospedale del Cuore G.Pasquinucci, Massa